

RES MEDICA

Journal of the Royal Medical Society



The Treatment of Head Injuries

J.W. Fowler M.B., Ch.B., F.R.C.S.E.

Abstract

Trauma has become the endemic disease of modern civilisation. Head injury occurs in 70% of all injuries and causes death in 25%. The number of significant head injuries is rising year by year as shown by the table of the figures at the Royal Infirmary of Edinburgh.

TABLE 1

Year	Number
1962	830
1963	691
1964	941
1965	1020
1966	1251

In no other system of the body is a knowledge of the functional anatomy more essential than in the diagnosis and treatment of the head-injured. The brain is contained loosely within the bony skull. It is separated from it by the meninges and by a subarachnoid layer of cerebro-spinal fluid (C.S.F.). The brain maintains continuity with the bony skeleton by means of the cerebral veins which pass from the cortical surface to the dural sinuses. The width of the space between brain and skull depends on brain bulk. Thus in states of cerebral atrophy due to age or disease the space will be increased.

Copyright Royal Medical Society. All rights reserved. The copyright is retained by the author and the Royal Medical Society, except where explicitly otherwise stated. Scans have been produced by the Digital Imaging Unit at Edinburgh University Library. Res Medica is supported by the University of Edinburgh's Journal Hosting Service: <http://journals.ed.ac.uk>

ISSN: 2051-7580 (Online) ISSN: 0482-3206 (Print)

Res Medica is published by the Royal Medical Society, 5/5 Bristo Square, Edinburgh, EH8 9AL

Res Medica, Spring 1971, 6(5): 27-33

doi:[10.2218/resmedica.v6i5.875](https://doi.org/10.2218/resmedica.v6i5.875)

THE TREATMENT OF HEAD INJURIES

J. W. Fowler, M.B., Ch.B., F.R.C.S.E.

Trauma has become the endemic disease of modern civilisation. Head injury occurs in 70% of all injuries and causes death in 25%. The number of significant head injuries is rising year by year as shown by the table of the figures at the Royal Infirmary of Edinburgh.

TABLE 1

<i>Year</i>	<i>Number</i>
1962	830
1963	691
1964	941
1965	1020
1966	1251

In no other system of the body is a knowledge of the functional anatomy more essential than in the diagnosis and treatment of the head-injured. The brain is contained loosely within the bony skull. It is separated from it by the meninges and by a subarachnoid layer of cerebro-spinal fluid (C.S.F.). The brain maintains continuity with the bony skeleton by means of the cerebral veins which pass from the cortical surface to the dural sinuses. The width of the space between brain and skull depends on brain bulk. Thus in states of

cerebral atrophy due to age or disease the space will be increased.

The bony confines of the skull consist of a smooth vault and occipital region. In relation to the anterior extremity of the temporal pole lies the extremely sharp area of bone, the lesser wing of the sphenoid. The skull contents may be divided into a supratentorial and an infratentorial portion. The features which influence the symptomatology in the supratentorial area, other than those described, are the arrangement of certain blood-vessels and nerves in relation to the bony skeleton. The middle meningeal vessels, entering via the foramen spinosum, run laterally along the floor of the middle fossa, extra-durally, carving a groove in the bone. In the lateral wall of the middle fossa this may become a bony tunnel, thus enclosing the vessels and making compensatory movement in any direction impossible.

The third nerve runs anteriorly from the mid-brain, along the medial side of the tentorial hiatus to pierce the dura at the side of the posterior clinoid process; lying immediately laterally and superiorly to it is the uncus of the temporal lobe.

The infratentorial space is small in volume with a smooth bony lining and contains medulla, pons, and cerebellum. Superiorly it is limited by the unyielding tentorium which splits peripherally to enclose the transverse and sigmoid sinuses.

PATHOLOGY OF SKULL INJURY

Brain injury may result from two forms of trauma:—

a) Static in which local damage to the skull is sustained, with little underlying damage to brain substance.

b) Acceleration/deceleration injuries in which bony injury is slight and brain damage severe.

a) Static injury

In this the head is stationary and a force acts directly on the skull. This usually causes a depressed fracture with local damage to the underlying brain. The mechanism is usually an object such as a stone or a hammer, etc., hitting the skull.

b) Acceleration/Deceleration injury

This is the form of injury as occurs when a person falls to the ground and strikes the head, or in car accidents, where the deceleration is severe and sudden.

The degree of injury produced by deforming forces depends upon both direction and momentum of the deforming force. The brain is free to move in an antero-posterior plane to a much greater extent than in a lateral one because of the stabilising action of the Falx. Thus frontal or occipital injury tends to produce the most severe brain injury. In acceleration/deceleration injury the lines of stress are maximal in the region of the brain-stem.

At the moment of impact there is severe distortion of the brain substance. The brain then accelerates in the direction of the force. When the skull comes to rest, the brain is carried into it by its momentum, thus being injured at two places a) at the site of the injury and b) at the point opposite to the injury, the 'contra-coup' effect. There may also be injury to the supporting veins.

In severe distortion not only does brain move in relation to skull, but grey matter moves in relation to white.

In concussion head injury the degree of displacement is slight, there is only physiological disturbance of function, followed by complete functional recovery.

More severe displacement causes the condition of confusional injury in which unconsciousness is prolonged, and initial recovery imperfect; and lastly laceration of brain substance where residual deficit always remains.

The first decision regarding a brain injury

is whether there is a significant injury or not. The seriously traumatised patient presents no problem. It is in the minor head injury that difficulty is experienced in selecting those cases requiring close observation.

There are three criteria employed in assessing the need for admission to the Head Injury Unit of the Royal Infirmary of Edinburgh, viz.,

a) A period of unconsciousness, however brief.

b) Skull or spinal fracture.

c) Should clinical judgement indicate that a period of observation be necessary, e.g. a history of high velocity accident with no apparent deficit.

There are two purposes of admission of a head injury to hospital, observation and secondly treatment.

Trauma to the head can cause death by both the severity of the original injury and by late complication of the injury.

The accurate assessment of a head injury depends upon the course the level of consciousness has followed from the time of injury, combined with the findings of the clinical examination.

The vital importance of a knowledge of the conscious level immediately following the accident cannot be over-stressed, therefore a history must be obtained from witnesses or the ambulance driver. In the South-eastern area of Scotland every ambulance carries a head-injury card which is pinned to the patient. On this is noted the state of consciousness of the patient at the time of the accident, in transit and on arrival in hospital.

Once in hospital a full neurological and general examination is carried out. Speed is essential in the care of the severely injured patient, and the development of a set routine is imperative for this.

1) The airway must be cleared and endotracheal intubation carried out if indicated.

2) The pupils, head and neck must be inspected for signs of cerebral compression or obvious cranio-cervical injury.

3) The blood-pressure and pulse must be recorded and an intra-venous infusion set up. Shock must be immediately treated. It is advisable to set up an I.V. infusion in any moderately traumatised patient, even if shock is absent, as the handling necessary in the proper assessment may produce collapse, and at this stage great difficulty may be encountered in setting up an I.V. infusion. Blood

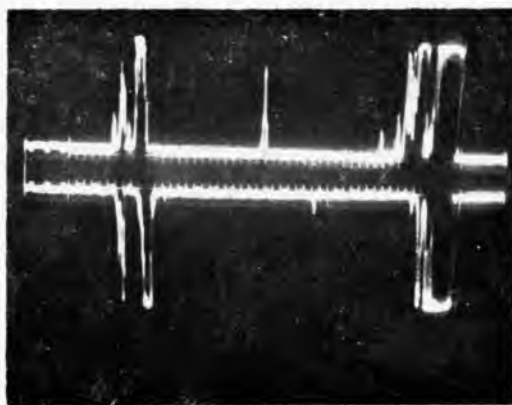

should be withdrawn for cross-matching at this point.

A note should be made of the conscious level; whether the patient is lucid and well-orientated, will obey commands easily and at what level of complexity, or whether he is drowsy but responding, reacting to the various degrees of pain, etc.

Clinical, radiological and echo-encephalographic base lines having been established, the patient's vital signs are monitored at frequent intervals, every 15 minutes in the first instance and increasingly as the patient recovers.

The treatment of the primary pathology of brain injury or uncomplicated skull fracture is observation.

Echo Tracing



The pulse, blood-pressure and respiratory rate are recorded.

The neurological findings are noted.

Radiological assessment is then carried out. This should include four films, namely postero-anterior, lateral and townes views of the skull, and at least a lateral view of all seven cervical and first thoracic vertebrae. An echo-encephalogram is helpful at this stage. Essentially this consists of placing a probe in the temporal region of the skull and sending high-frequency sound waves through the bony structures to bounce off the mid-line structures. A polaroid photograph is then taken of the tracing.

The probe is used from right to left and from left to right. The mid-line structures should coincide in both directions. The ECHO is a very useful ancillary investigation which may give some warning of an intracranial haematoma. The displacement has to occur at or near the temple however and an occipital or frontal displacement may not be shown. Too much reliance must not therefore be placed on this investigation.

THE VITAL SIGNS

1) Pulse

An injured patient will usually have a tachycardia. This will gradually fall to a normal level with rest. In the face of intra-cranial compression the pulse may show an initial increase in rate, and then a progressive fall, the rate of fall depending upon the rate of accumulation of clot or swelling of brain. Should the rate fall to 60 beats or less/min. then cerebral compression should be assumed until proved otherwise.

2) Blood pressure

In the face of cerebral compression the vasomotor centre is rendered anoxic. It responds firstly by causing a widening of the pulse pressure, followed by an increase in both systolic and diastolic pressures. Terminally there is cardiovascular collapse.

3) Respiration

In cerebral compression this shows a progressive fall in rate, maintaining a regular rhythm initially, but becoming deeper. It then

becomes periodic (Cheyne-Stokes breathing) followed by respiratory arrest.

4) Conscious level

This is the most reliable of all the clinical signs. The patient may become a little confused having been lucid previously. He may become dysphasic and will become gradually more and more unresponsive as the intracranial pressure rises.

5) Neurological state

a) The state of the pupils is of vital importance. Change in pupillary reaction is usually a late sign of cerebral compression. At first the pupil on the affected side may be smaller and then a little larger than its fellow, but react to light, at first briskly and then more and more sluggishly, until it remains dilated and fixed. The homolateral is the first affected. This is due to the depression of the uncus into the tentorial hiatus, leading to compression of the third nerve. As the pressure grows, the mid-line is displaced to the opposite side and the contralateral third nerve is then compressed, leading to bilateral dilated pupils.

In the face of greatly raised supra-tentorial pressure the medial aspect of temporal poles herniate down through the tentorial hiatus causing compression of the mid-brain structures.

b) Limb signs. In the classic intra-cranial haematoma the motor cortex is compressed leading to contra-lateral limb spasticity with positive Babinski response. As the pressure rises, and the mid-brain is compressed, the contra-lateral cerebral peduncle becomes compressed by the margins of the tentorial hiatus, leading to ipsilateral limb spasticity and positive Babinski response. It is therefore vital to assess all signs in conjunction.

The most important feature in the build-up of an intra-cranial haematoma is depression of the level of consciousness, with associated increasing restlessness. Again it should be stressed that it is the change in conscious level from the time of the accident that is important.

Any alteration in the vital signs calls for urgent reappraisal of the clinical situation.

The person who has been severely injured may be unconscious at the time of the accident and remain so. The level of consciousness and reactivity to stimuli being noted, it is then possible to assess whether the conscious level improves or not.

Should it improve, then the care of the unconscious patient is all that is necessary.

Should the level deepen, then urgent re-assessment and a search for cerebral compression should be carried out. If the reason is not readily apparent, then burr-hole exploration at least should be carried out.

TREATMENT OF PRIMARY PATHOLOGY

The three main causes of unconsciousness are:—

- a) Diffuse neuronal disruption.
- b) Brain-stem injury.
- c) Cerebral compression.

Immediate treatment of all unconscious patients:—

- 1) Clearing and maintenance of the airway.
- 2) Emptying of stomach via naso-gastric tube.
- 3) Regular monitoring of vital signs.
- 4) Treatment of any cuts, with Anti-tetanus toxoid and penicillin cover.
- 5) Care of the bladder; initially use only Paul's tubing and only catheterise if absolute retention occurs.
- 6) Maintenance of electrolyte balance.

THE DECEREBRATE PATIENT

In acceleration and deceleration injuries the brain-stem bears the brunt of the force. Injury to this area causes unconsciousness with decerebrate signs in all limbs. The state is present from the time of injury and should be diagnosed when this is so.

The clinical signs of brain-stem injury are:—

- a) Unconscious from the time of injury,
- b) Decerebrate rigidity,
- c) Hyperpyrexia,
- d) Constricted pupils.

Should all these conditions not apply, then cerebral compression should be assumed and the appropriate action taken.

PRIMARY BRAIN-STEM INJURY

In this injury the most dangerous complications are decerebrate rigidity and hyperpyrexia.

Decerebrate rigidity causes increased intrathoracic pressure with increased central venous pressure, and raised intra-cranial venous pressure. Thus any small haematoma may be rapidly enlarged. The increased muscle activity will cause an increase in the level of CO₂.

production, and this, along with an interference with respiration, will lead to acidosis and cerebral vein distension.

The hyperpyrexia, which is partly produced by damage to the regulating mechanism, and partly by increased heat production from muscle activity, causes a reflex increase in the respiratory rate; this leads to a less effective inspiratory volume and may lead to oxygen lack.

The decerebrate rigidity and hyperpyrexia may be treated by giving Sparine or Largactil 100 mg. t.i.d. or q.i.d. as necessary. Once the diagnosis of brain-stem injury has been made, it is beneficial to place the patient on an artificial ventilator and curarise him. This is followed by a fall of all the parameters to normal. It is normal to continue ventilation for 48 hours.

Other methods of cooling include aspirin, tepid sheets and fanning. Cooling should be started early, when the temperature is on the rise, and should be aimed at keeping a core temperature of 98-99° F. Shivering should not be induced as it would increase the heat production.

Still under primary pathology may be considered :

DEPRESSED FRACTURES

These may be divided into two groups, namely

- a) The smooth depression of less than the cortex in depth, and
- b) The sharp spiculated depression.

The first needs no treatment other than that of the unconscious patient. The second requires elevation of the fragments.

Should either injury be compound, then operative intervention is indicated, with excision of the wound, autoclaving and replacement of the fragments, if possible, and antibiotic cover, usually penicillin and sulphadiazine, together with anti-tetanus toxoid.

TREATMENT OF SECONDARY PATHOLOGY

Secondary pathology may be listed as follows:—

- 1) Extra-dural haematoma
- 2) Sub-dural haematoma
- 3) Rhinorrhoea

Aetiology: Fractured nose including cribriform plate. This indicates that the subarachnoid space is compromised and the patient in danger of contracting meningitis.

Treatment: (a) Conservative, prophylactic antibiotics, Penicillin and Sulphadiazine. The patient warned not to blow the nose.

(b) Operative: If the discharge is profuse or continuous for ten to 14 days, operative exposure and dural closure is undertaken.

Otorrhoea. CSF discharge from the ear almost always ceases spontaneously.

- 4) Brain swelling
- 5) Traumatic epilepsy
- 6) Meningitis
- 7) Hydrocephalus
- 8) Pulmonary oedema
- 9) Gastric erosion.

EXTRA-DURAL HAEMATOMA

In the early stages, the haematoma being extra-dural, there is no associated brain damage. As the pressure builds up the cortex becomes progressively compressed and if it is not relieved death occurs. The decompression of an extra-dural haematoma should be carried out swiftly by the diagnosing doctor or unit, unless access to a specialist unit is available within a few minutes. Should this not be done, then a patient, potentially curable, may be condemned to decerebration or death.

Extra-dural haematomas lie mainly in the middle temporal fossa. They are close to the site of injury or occasionally contra-coup. They are usually due to rupture of a branch of the middle meningeal artery or vein. Occasionally they may be frontal or occipital in situation, due usually to venous damage.

The mortality of operating upon a conscious patient is 5%. It becomes 75% when pupillary dilatation or unconsciousness supervenes. The morbidity is even higher.

Operative treatment of extra-dural haematoma.

The burr hole.

The first is placed at the site of the fracture or haematoma. Should this be negative, then one is placed in the contra-coup area.

PLACEMENT OF BURR HOLE

- i Contralateral to hemiparesis
- ii Side of Dilating Pupil
- iii Side of superficial Haematoma
- iv Side of fracture.

SUBDURAL HAEMATOMA

The primary pathology is usually acceleration/deceleration injury with severe brain distortion and either rupture of veins, laceration of brain or both. The haematoma usually arises from injury to parietal or temporal poles, or occasionally from the tearing of a cerebral vein.

The haematoma may be fluid or clot. It is usual to do six burr holes in an exploration for a sub-dural haematoma. In the acute subdural following localisation of clot, it is usually necessary to do the appropriate craniotomy. The chronic subdural, which is usually fluid, can be released via burr holes. These are bi-frontal, bi-temporal and bilateral posterior parietal. They are all carried out bilaterally because 50-70% of subdural haematomas are bilateral. Should a fluid haematoma be encountered, then all that is required is that it be washed away with saline using a fine rubber catheter, introduced via a burr hole. A clotted sub-dural haematoma requires the turning of a bone flap.

Again it should be stressed that the compression caused by the haematoma causes severe brain damage, and should be relieved as soon as possible after diagnosis. Once the clot has been released through a burr hole, then time is available for the transfer of the patient to a specialist unit, or for the flying squad to reach him.

BRAIN SWELLING

Cerebral oedema consists mainly of an increase in intra-cellular fluid, with some increase in interstitial fluid. This causes great expansion of the brain tissues, and ultimately compression of the brain within the bony skull. The supratentorial increase in pressure may cause coning (downward herniation of the uncus through the tentorial hiatus) and death. Brain swelling may be local or diffuse; it may appear quickly or take some time to develop. The signs of cerebral swelling do not differ in any way from the clinical picture of raised

intra-cranial pressure. If there is any doubt then burr hole exploration should be carried out to exclude any remedial cause.

The actual pathology of the situation is far from clear; possibly following the distortion and cellular damage oedema occurs as in any other situation; this in turn causes congestion and occlusion of blood vessels, leading to anoxia which further increases the damage, leading to further oedema. Superimposed upon this may be an obstructed airway, low pO_2 , increased pCO_2 , all leading to cerebral vascular dilatation and stasis and a decrease in general cerebral perfusion.

The brain tissue is therefore subjected to:—

- a) Increased tissue tension,
- b) Vascular occlusion,
- c) Anoxia,
- d) Raised venous pressure.

It is not altogether surprising that it reacts as it does.

TREATMENT

Accurate diagnosis and the exclusion of intra-cranial clot is the first step.

Should the oedema become intractable then internal decompression is done; this involves removal of the affected part if it is destroyed, or of one of the silent areas usually the right frontal lobe. This allows the remaining brain tissue room to expand. It is of no avail to remove part of the skull, as the brain herniates through the space, causing kinking of the veins and venous infarction thus serving no purpose.

Osmotic diuresis induced by mannitol 25% procures a little time; the effect lasts for 3-4 hours and is usually followed by further and often increased cerebral oedema. During this time, dexamethazone, an anti-inflammatory steroid, may be given, 10 mg. I.V. to start with and then 4 mg. q.i.d., reducing the dosage over the next eight days.

VENTILATION

By placing the patient on a ventilator three things are accomplished:—

- a) Normal O_2 saturation to the brain tissue.
- b) The pCO_2 level may be maintained at 30 mm Hg. At this level there is slight intra-cranial vascular constriction thus reducing the tissue tension.

c) Any increase in temperature or muscle tone can be abolished.
It is usual to keep the patient on the ventilator for 48 hrs., the oedema usually subsiding in this time.

TRAUMATIC EPILEPSY

This occurs in 3-5% of head injuries. It may be either immediate or delayed.

Epilepsy may be a manifestation of concussion, laceration or overlying haematoma. Treatment consists of excluding an overlying haematoma and controlling the fits. This may be carried out using Epanutin, and if this is unsuccessful, Valium may be used. Should these be ineffective, then I.V. Paraldehyde or a Pentothal drip may be used.

MENINGITIS AND HYDROCEPHALUS

The treatment of these conditions is standard.

PULMONARY OEDEMA AND GASTRIC OR DUODENAL EROSION

These are infrequent complications of head injury. They are mediated via the hypothalamic nucleus and the autonomic nervous system.

Experimentally pulmonary oedema may be abolished by the beta sympathetic blockade using propranolol. In practice, it may be adequately treated by positive pressure ventilation which drives the fluid back into the capillaries.

Gastro-intestinal bleeding must be treated in the usual manner.

In the case which presents difficulty or which is deteriorating slowly, or remaining static, angiography may be employed. These investigations will usually show the position of any surface or intra-cerebral clot.

The management of the head-injured places a premium upon accurate initial clinical assessment and continuous reappraisal. It makes definitive thinking and action imperative. In no other area in the treatment of the accident case, can lives be saved so easily or ruined so completely.

My thanks go to Mr. J. F. Shaw for his advice on the preparation of this article.

H. K. LEWIS & Co. Ltd.

FOURTH EDITION IN SIX VOLUMES

A TEXT-BOOK OF X-RAY DIAGNOSIS

Edited by S. COCHRANE SHANKS, C.B.E., M.D., F.R.C.P., F.F.R.
and PETER KERLEY, C.B.E., C.V.O., M.D., F.R.C.P., F.F.R., D.M.R.E.

- Volume I. **THE HEAD AND NECK.** 669 illustrations. £8 10s. net.
Volume II. **THE CARDIOVASCULAR SYSTEM.** In Preparation.
Volume III. **THE RESPIRATORY SYSTEM.** In Preparation
Volume IV. **THE ALIMENTARY TRACT.** 557 illustrations. £8 10s. net.
Volume V. **THE ABDOMEN.** 400 illustrations. £7 net.
Volume VI. **BONES, JOINTS AND SOFT TISSUES.** 869 illustrations. In the Press.

GYNÆCOLOGICAL & OBSTETRICAL ANATOMY

DESCRIPTIVE AND APPLIED

By C. F. V. SMOUT, M.D., F. JACOBY, M.D., Ph.D., and E. W. LILLIE, M.D., F.R.C.O.G.
Fourth Edition. 182 illustrations. £4 10s. net, postage 4s. 6d.

BASIC DERMATOLOGY

By P. J. HARE, M.D., F.R.C.P. 280 illustrations in
61 figures. 9½ in. x 6½ in. £2 10s. net, postage 3s.

ROXBURGH'S COMMON SKIN DISEASES

13th Edition by PETER BORRIE, M.A., M.D.,
F.R.C.P. 239 illustrations. £3 net, postage 4s. 6d.

Obtainable of all Booksellers

136 GOWER STREET, LONDON, WC1E 6BS.

'Phones: 01-387 4282

'Grams: Publicavit, London, W.C.1