

RES MEDICA

Journal of the Royal Medical Society



The Rectal Examination

John B. Dawson
M.A., B.M., B.Ch., M.R.C.P.Ed.

Abstract

A quotation attributed to one of England's leading rectal surgeons, fondly known as the "Rear Admiral", states: "If you do not put your finger in, you will put your foot in it" ; implying that a routine " physical" is not complete without a competent rectal examination, and failure to acknowledge this fact may lead you and your patient into serious trouble.

Words such as distasteful, repugnant, inaesthetic, are often chosen to describe the "rectal" . Such adjectives in this context stem from a false modesty and the complicated rituals of excretion which afflict a modern urban civilization. The result is that many people consider a per rectum (P.R.) examination to be an affront to the person or at least "not quite nice". Negative attitudes of this kind cannot be tolerated within the profession who must accept a P.R. as the routine final act of the complete physical examination.

Copyright Royal Medical Society. All rights reserved. The copyright is retained by the author and the Royal Medical Society, except where explicitly otherwise stated. Scans have been produced by the Digital Imaging Unit at Edinburgh University Library. Res Medica is supported by the University of Edinburgh's Journal Hosting Service: <http://journals.ed.ac.uk>

ISSN: 2051-7580 (Online) ISSN: 0482-3206 (Print)

Res Medica is published by the Royal Medical Society, 5/5 Bristo Square, Edinburgh, EH8 9AL

Res Medica, Summer 1968, 6(2): 28-32

doi: [10.2218/resmedica.v6i2.842](https://doi.org/10.2218/resmedica.v6i2.842)

THE RECTAL EXAMINATION

JOHN B. DAWSON, M.A., B.M., B.Ch., M.R.C.P.Ed.

Health Sciences Centre, New York

INTRODUCTION

A quotation attributed to one of England's leading rectal surgeons, fondly known as the "Rear Admiral", states: "If you do not put your finger in, you will put your foot in it"; implying that a routine "physical" is not complete without a competent rectal examination, and failure to acknowledge this fact may lead you and your patient into serious trouble.

Words such as distasteful, repugnant, in-aesthetic, are often chosen to describe the "rectal". Such adjectives in this context stem from a false modesty and the complicated rituals of excretion which afflict a modern urban civilization. The result is that many people consider a per rectum (P.R.) examination to be an affront to the person or at least "not quite nice". Negative attitudes of this kind cannot be tolerated within the profession who must accept a P.R. as the routine final act of the complete physical examination.

Nevertheless, because of such sensitivities within the public at large, due respect must be shown both in method and approach. In communities where cancer prevention by early detection is fully developed, the digital rectal examination forms part of an accepted annual program, which suggests that the climate of acceptance is a matter of education.

Whatever the reaction, the perpetration of a callous, rough, and thereby painful "rectal" upon the captive patient, as so eloquently portrayed by O'Grady (O'Grady, 1963), is a

disgrace to our profession. To prevent this occurrence I believe it is essential that a doctor should submit himself to a digital P.R. at an early stage in his career. One distinguished colleague feels so strongly on this point that he not only expects his students to examine each other by digital examination, but requires them to undergo subsequent sigmoidoscopy. Only after such an experience can you confidently give instructions to your patient with a convincing explanation of what he can expect during your own "routine procedure".

Some such explanation is vital for the success of your examination because manoeuvres, which are novel to a patient, and during which he cannot view the field of operation, are the ones that cause the greatest apprehension. Failure to realize this association will encourage the development of a degree of patient perianal spasm which will reduce by half the internal area accessible to your exploring finger, and his worry unconsciously conveyed to you will cause you to use undue haste and will prevent you from thinking constructively while engaged in the actual investigation. The injunction both for you and the patient is **TO RELAX**.

THE EXAMINATION

Rectal examination is a composite term and, if there be suspicious symptoms or signs, will include more than a mere digital diagnostic

Scopy — Skopein — Gk. — To examine.
Procto — Proktos — Gk. — Anus — (combination form to include rectum and anal area).
Recto — Rectum — L. — Straight:— (extends from 3rd

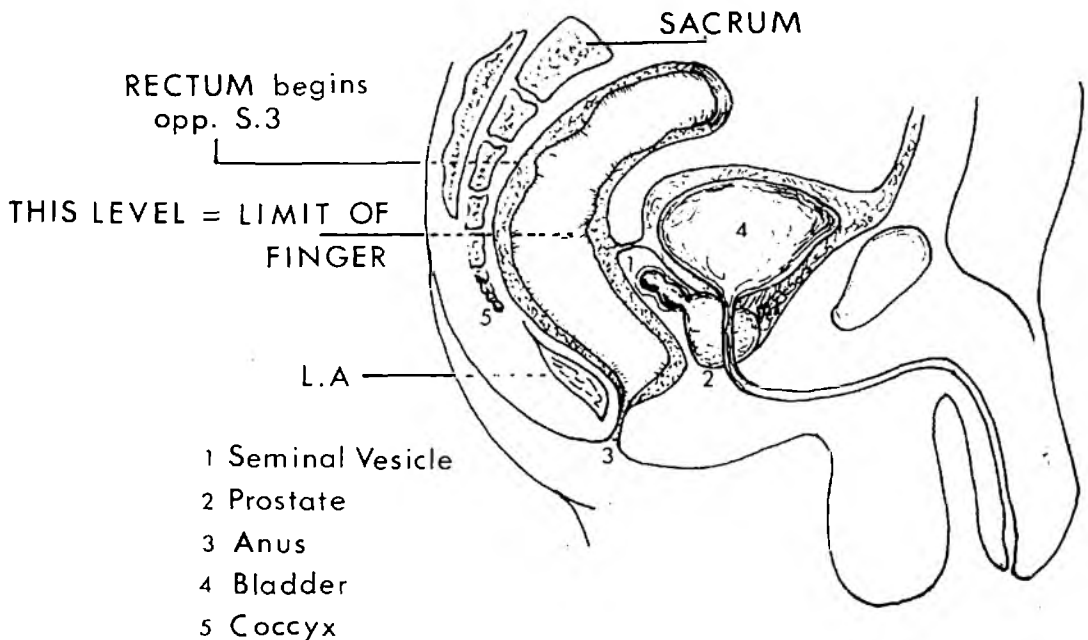
sacral vertebra to the anal canal).
Sigmo — Sigmoides — L. — "S" shaped.
Colon — Kolon — Gk. — Extends from caecum to rectum.

exploration with the forefinger. Symptoms and signs of change in bowel habit, persistent diarrhoea, pain in the abdomen, back or anal region, unexplained anaemia, the passage of blood, mucous or pus P.R., the protrusion of rectal mucosa, symptoms of prostatic hypertrophy and abnormal vaginal discharge are a few of the criteria which make a P.R. and a subsequent sigmoidoscopy mandatory and a radiological investigation of the terminal colon highly likely. This approach applies to infants and small children every bit as much as to adults, the only differences being that the little finger is used for the P.R., as for the neonatal check for imperforate anus, while a smaller sigmoidoscope is chosen for the follow-up.

established cancer of the cervix, the second commonest cancer in women, will be easily palpable through the anterior rectal wall.

Another of the many reasons for insisting upon the digital P.R. as part of a doctor's physical examination routine is the report that some 75% of large bowel tumours occur in the rectum and sigmoid colon and 50% of those that are cancerous will be within range of your probing forefinger. Some idea of the problem at large was presented by the American Cancer Society.

"In 1961, there were 70,000 cases of cancer of the colon and rectum in the U.S.A., two-thirds of whom under present conditions die."



A planned internal digital exploration of the area with the addition of bimanual palpation, to be discussed later, will always detect the sacro-tuberous ligaments, usually sense the sacrospinous ligaments, and will define the normal or abnormal condition of the anus and levator ani, the bladder, the prostate and seminal vesicles, the coccyx, the uterus (where relevant) and the lower rectum.

The full extent of the recto-uterine pouch, with its tendency to collect pus as a pelvic abscess, or metastatic carcinomata, is readily accessible to your exploring finger, while an

Such figures provide a strong foundation for those who argue in favour of an annual rectal examination as part of a program for the early detection of cancer.

The incidence of cancer of the rectum in a general practice is likely to be in single figures during the principal's lifespan. Nonetheless, no practitioner would ever forgive himself if he avoidably missed an operable growth, and by doing so sentenced his patient to a most unpleasant mode of death (Birnbbaum 1964).

Assuming there are definite symptoms and signs present which make a "rectal" essential,

a planned preparation of the patient to assist towards an optimal result is worthwhile. If the patient can wait 24 hours before attending at your "office" or is a hospital in-patient, a few simple preparatory measures merit consideration and include:—

- 1) The provision of a light diet — low in bulk — with an emphasis on plenty of fluids for some 24 hours before your examination is due.
- 2) The administration of a mild dose of laxative such as a tumblerful of "Senokot" laced warm milk on the previous evening.
- 3) The rectal implantation of one or two mild suppositories of the Dulcolax-Senokot type or the giving of a small volume saline enema some 4 hours before time zero.

Inability to carry out these simple preparatory procedures does not forecast the failure of your rectal examination, but such preparations do contribute to success in the first instance and repeated rectal manipulation does not make for good doctor-patient relationship!

Consider, before you begin your examin-

ation, whether any other consultants are likely to be called in at a later stage, and if possible arrange for them all to be present at the one examination. If this cannot be, it is kind to limit further rectal investigation to the operating theatre with the patient under an anaesthetic.

Plan your examination. Always arrive at the time you stated to the patient so that he is spared the added worry of apprehensive waiting and choose the afternoons, when the motions tend to be firmer (less fluid). A well-driven sigmoidoscope should easily bypass faecal lumps, but should they cause trouble they can easily be removed when not too soft. As a rule preparation of the rectum and colon immediately prior to the P.R. is not advisable. A soft soap enema will not only irritate the mucosa and thereby change its characteristic appearance, but will remove important tell-tale traces of pus, mucus or blood. Similarly excessive warming of the sigmoidoscope may considerably alter the appearance of the rectal lining and thereby obscure or change a vital diagnostic sign.

When you have accepted the P.R. as part of your routine "physical" check, the best

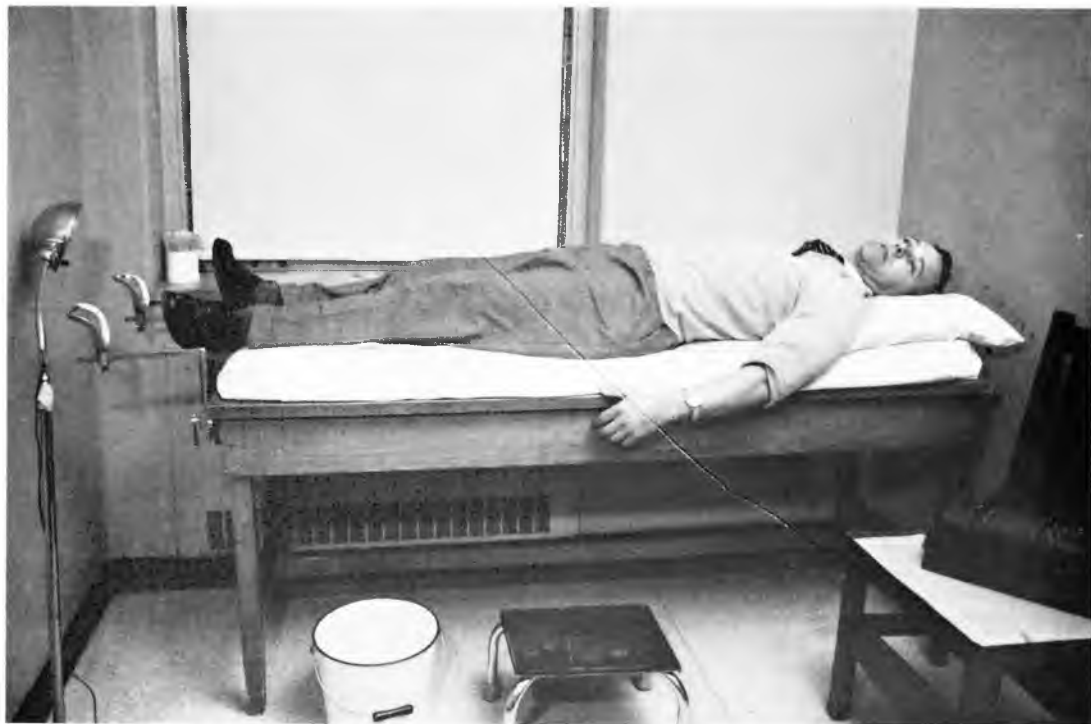

Fig. 1

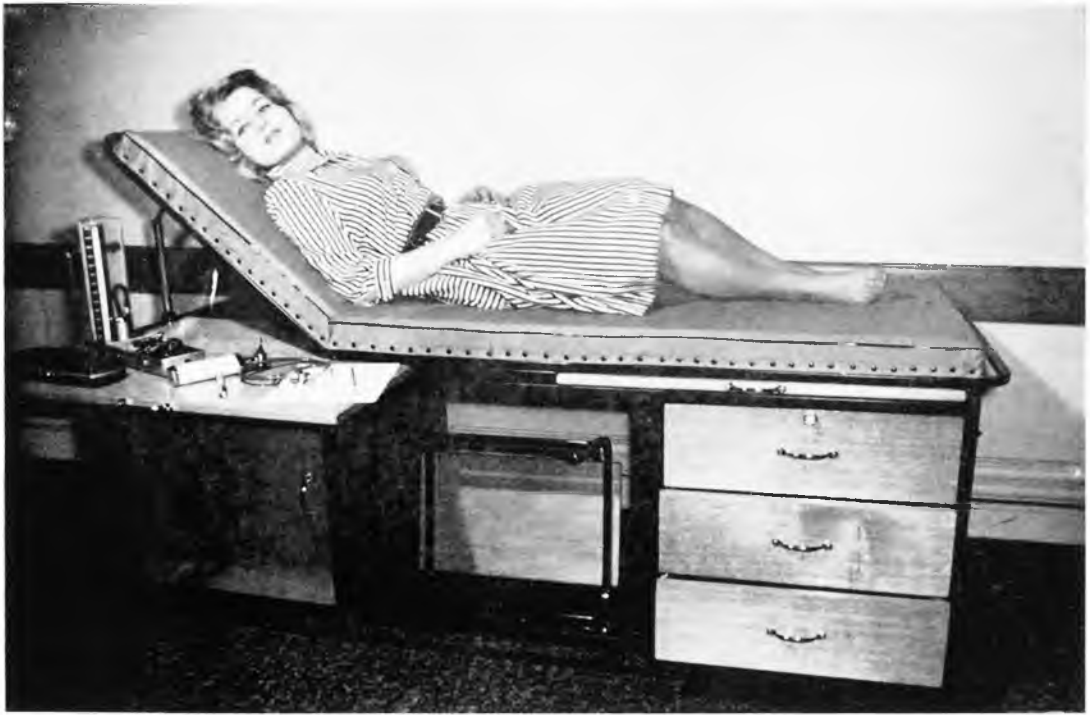

Fig. II

approach to the patient is to spring the idea upon him quite impersonally and after all else is completed. Explain that you feel it is a necessary conclusive act and proceed to instruct him in what you want him to do and what he is likely to feel in terms of:—

"To round off this examination, Mr. Davis, I now wish to examine your back passage with a gloved finger to make sure all is correct. You will find the procedure only mildly uncomfortable and will experience a sensation as though you were passing a motion; you are not to worry about this, it is only the effect of my examining finger moving in your anal canal, and you will feel no pain." Go on to explain that he is not to worry about an examination that he cannot view because you will comment as you go; that it will be a great help to you if he will breathe quietly and deeply and to relax himself as much as possible. Should he feel pain he is to let you know — for diagnostic and humane reasons — but the whole procedure being strange to him is bound to be a little uncomfortable.

It is worth remembering that a rectal digital approach is a very good substitute for a "vaginal" examination in the virgin and pre-marital woman, and can be relied upon for pelvic investigation of a non-obstetrical nature.

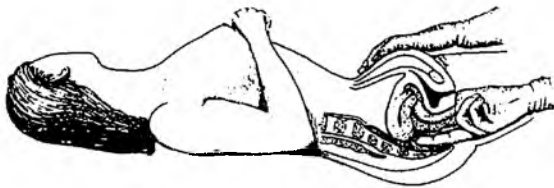
To ensure success in terms of information to be gained and in the maintenance of a good doctor-patient relationship, obtain a degree of modest privacy or a satisfactory chaperone and ask the patient to climb upon a suitable couch. A suitable couch in terms of adult examination, contrasted with the general hospital bed, implies a solid construction with dimensions of 6' x 3' and which is covered to a depth of at least 2" by a material such as foam rubber padding. One unsatisfactory couch and one designed by the author, constructed locally with an imported overburden, can be seen in figures I and II respectively.

Once the patient is settled, remove the obstructing clothes, but keep the "bare bottom" covered until you are ready. Then, place the subject in one of the three commonly used positions:

1) The "left lateral" position — with the upper legs well-flexed at the hips and the lower leg flexed to 90 degrees at the knees, the upper right leg at both points being slightly more flexed than the lower left, while the long axis of the body lies almost across the couch. This is perhaps the most satisfactory position for the frail, the elderly, or at the beginning of your practice in these areas, because by gently parting the buttocks you can satisfactorily expose the area of operation, you need not look the patient in the eye, and it is, on the whole, a gentler affair.

However, you cannot achieve as much as with:—

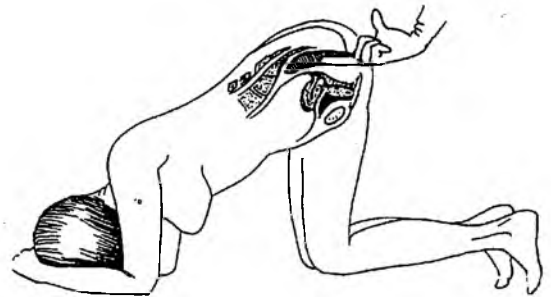
2) The "dorsal" position, in which the patient lies supine with knees and hips flexed and slightly parted. With your finger in the rectum watch the patient's face to see that you are not being too rough while you use the other hand to suprapubically palpate the anterior abdominal wall. By this action of bi-manual palpation and with good patient relaxation you can discover almost all of the abnormalities lurking in the lower pelvis. This is a particularly useful approach when you wish to assess the size and condition of the bladder-prostate-seminal vesicles, uterus, tubes or ovaries and their pathological variants.



3) The *third* position — excellent for the operator, but tiring and unconventional for the patient if a flat surface is used, as opposed to a stepped and tilted surface, is referred to as the "knee-elbow", a name which is self-explanatory.

The advantage of this position is that it offers a magnificent view of the superficial anal area and the action of gravity will cause the

"guts" to fall away from you when you come to follow your digital examination with sigmoidoscopy, thus making the introduction of this lengthy instrument (25 cm.) more simple and less traumatic.



For practical purposes I would suggest a progression of method. Begin with the patient in the lateral position, then with your examining finger still in situ, rotate the patient into the supine position, and then if relations are still satisfactory proceed with sigmoidoscopy in the knee-elbow position. If the patient seems distressed, it may be politic to revert once more to the lateral position for the sigmoidoscopy.

There are few acceptable exceptions to a routine rectal. An emotional child of impressionable age whose full cooperation is vital to therapy and in which no alimentary trouble is suspected is one in whom the examination can be delayed or perhaps abandoned. Similarly a young woman in menstruation presents an emotionally charged situation which may be inaeesthetic to both operator and patient alike and it may be preferable to postpone examination until the flow has ceased. The very ill are another group in which a rectal can be postponed; but postponement, not abandonment, is the program. Patients, especially the elderly, can, and do, have multiple 'pathology'.

REFERENCES

- Birnbaum, W. (1964): "Sigmoidoscopy Defended". *Jama*, Vol. 190 (1) p.81.
 O'Grady, John, (nino culotta) 1963: *The Things They Do To You*. Ure Smith Pty, Ltd.

The next issue of RES MEDICA will contain the second half of this article.