



CLINICAL AUDIT ARTICLE

Audit into the Appropriateness of CT Cervical Spine Scan Requesting in the Emergency Department

Marc A Jacobson¹, Damien Ryan² MRCSI, MRCSEd(A&E), DIMC, FCEM

¹ Medical Student, University of Limerick, Limerick, Ireland

² Consultant in Emergency Medicine, Emergency Department, University Hospital Limerick, Dooradoyle, Limerick, Ireland

Correspondence email: 11057262@studentmail.ul.ie

Abstract

Introduction: The use of computed tomography (CT) imaging of the cervical spine (CS) is now the recommended primary screening modality for suspected CS injuries following trauma. The aim of this audit is to review the appropriate use of CS CT imaging in the emergency department (ED) and assess compliance with the National Institute for Health and Care Excellence (NICE) head injury clinical guidelines.

Methods: Charts were reviewed for the last 50 trauma patients to receive a CS CT scan following a request from the ED at University Hospital Limerick between 10 July 2013 and 19 December 2013. The NICE clinical guideline 176 on head injury was used as the standard of care. These data were used to perform a retrospective audit to assess patients who satisfied NICE criteria to qualify for a CS CT scan.

Results: 45 patients who had undergone a CS CT scan were identified, this group had a mean age of 42 years and 71% of them were male. At least one of the NICE guideline criteria was fulfilled in 100% of patients who had a CS CT, with 2.64 of the criteria fulfilled on average. Plain-film X-ray radiography (PF) was inadequate for diagnosis in 20 (44.4%) patients.

Discussion: ED consultants appropriately refer patients for CS CT scans following CS trauma and adhere to NICE head injury clinical guidelines.

Conclusion: Having guidelines in place in the ED and adopting CS CT imaging as an initial screening modality following CS injury may reduce time to definitive care and improve resource implications.

Copyright Royal Medical Society. All rights reserved. The copyright is retained by the author and the Royal Medical Society, except where explicitly otherwise stated. Scans have been produced by the Digital Imaging Unit at Edinburgh University Library. Res Medica is supported by the University of Edinburgh's Journal Hosting Service: <http://journals.ed.ac.uk>

ISSN: 2051-7580 (Online) ISBN: 0482-3206 (Print)

Res Medica is published by the Royal Medical Society, 5/5 Bristo Square, Edinburgh, EH8 9AL

Res Medica, 2014, 22(1): 120-125.
doi:10.2218/resmedica.v22i1.812

Audit into the Appropriateness of CT Cervical Spine Scan Requesting in the Emergency Department

Introduction

Injury to the cervical spine (CS) is common after major trauma¹ with an incidence of 2–4%.² A missed CS fracture as a consequence of inadequate imaging has the potential for significant morbidity and litigation costs for the hospital.² Plain-film X-ray radiography (PF) is inadequate in visualizing the complete CS in a large proportion of patients³ and a standard CS PF image fails to identify all patients with CS injuries.⁴ As a minimum, computed tomography (CT) should be performed if there is any concern from the PF or on clinical grounds.⁵ The Eastern Association for the Surgery of Trauma has published practice management guidelines for the screening of suspected CS injury following trauma. They recommend CS CT imaging should replace PF imaging as the primary imaging modality. This should include axial images from the occiput to thoracic vertebra T1 with sagittal and coronal reconstructions in order to provide increased definition that would allow radiology to exclude significant spinal injury.¹ The National Institute for Health and Care Excellence (NICE) recently updated their head injury clinical guidelines in January 2014, which helps to identify

patients who require CS CT imaging following admission to the emergency department (ED) with trauma to the CS.⁵

The purpose of this audit is to assess the appropriate use of imaging resources (CS PF and CS CT imaging) in the ED of University Hospital Limerick (UHL). This is the regional trauma centre, receiving an average of 60 000 new patients per year. The NICE clinical guideline 176 on head injury was used as the standard of care.

The primary outcome was to assess compliance with the clinical guidelines for the use of CS CT imaging in the ED. Secondary outcomes included potential medical implications for the patient (e.g. missed diagnosis and radiation dose) and the balance between clinical care and appropriate resource utilization in the hospital.

Methods

A retrospective audit was conducted on 50 patients who received a CS CT scan (Siemens SOMATOM Sensation 64 Slice) following a request from the ED made between 10 July 2013 and 19 December 2013. The National Integrated Medical Imaging System (NIMIS), a computer-based system for storing and examining imaging scans, was searched for the last 50 requests for CS CT imaging. Inclusion criteria consisted of all CS CT imaging requests

made through the ED, by ED consultants. Exclusion criteria comprised requests made by non-ED staff; consequently 5 requests were excluded for the purpose of this audit. UHL uses the ADOS computerized document management system for processing, indexing, storing, and managing patients' ED charts. These were reviewed to assess for risk factors based on the NICE guidelines.⁵ These state that a CS CT scan should be performed in adults who have sustained a head injury within 1 hour of a risk factor being identified (Table 1).

Additionally, patients' PF scans were interpreted by the ED consultant and radiologist.

Table 1: Risk Factors that would indicate CT Head

<ul style="list-style-type: none"> • Glasgow Coma Scale (GCS) score < 13 on initial assessment; the GCS is a scale of consciousness for the evaluation of head trauma⁶ • The patient has been intubated • PF images are technically inadequate • PF images are suspicious or definitely abnormal • A definitive diagnosis of CS injury is needed urgently • The patient is having other areas of the body scanned for head injury or multiregion trauma • The patient is alert and stable, there is clinical suspicion of CS injury, and any of the following apply: <ul style="list-style-type: none"> ○ Age 65 years or older ○ Dangerous mechanism of injury (fall from a height of greater than 1 m or 5 stairs, axial load to the head, high-speed motor vehicle collision, rollover motor accident, ejection from a motor vehicle, accident involving motorized recreational vehicles, bicycle collision) ○ Focal peripheral neurological deficit ○ Paraesthesia in the upper or lower limbs.

Results

Forty-five patients were included with a mean age of 42 years (range: 2–87). 32 (71.1%) were male and 13 (28.9%) were female (Table 2). At least one of the NICE criteria was fulfilled in all 45 patients who underwent a CS CT scan (Figure 1). On average, 2.64 of the criteria were fulfilled with 27 (60.0%) patients identified as having at least 3 or more criteria (Figure 2). PF scans were inadequate for diagnosis in 20 (44.4%) patients. Of the trauma mechanisms, 23 (51.1%) were road traffic accidents, 18 (40.0%) were falls, and the remaining 4 (8.9%) had other causes. The median GCS on initial evaluation in the ED was 14.5 (range: 3–15).

Table 2. Age and sex distribution of the 45 trauma patients

Sex	Age 0–18 (n)	Age 19–25 (n)	Age 26–55 (n)	Age 56–65 (n)	Age > 65 (n)
Males	5	4	12	6	5
Females	5	2	2	1	3

Figure 1. Graphical representation of the number of patients positive for each of the risk factors listed in the NICE head injury criteria for CS CT imaging following trauma

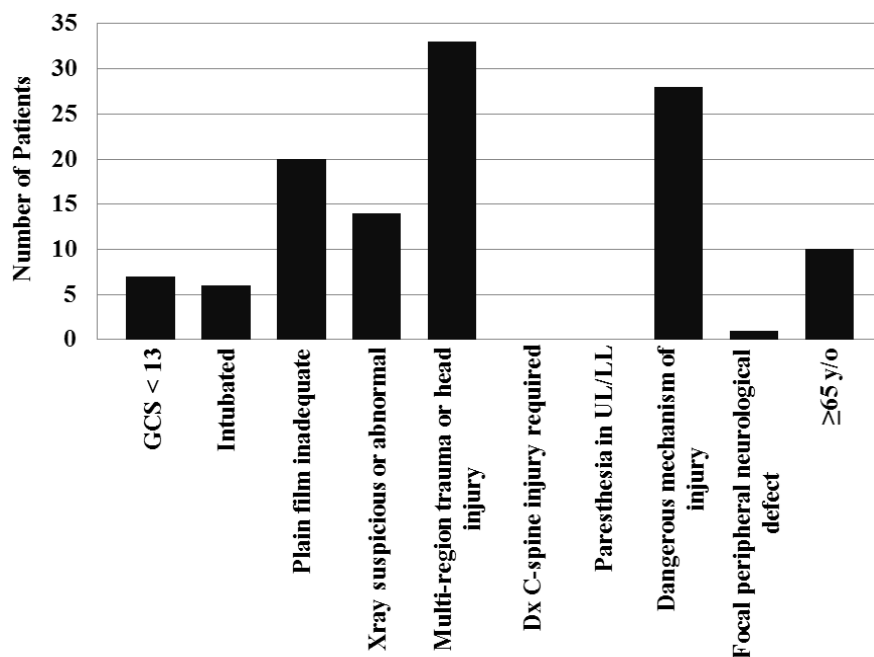
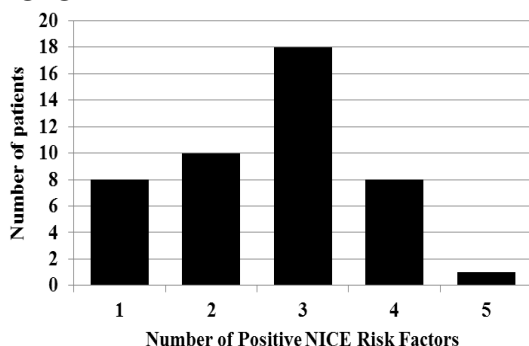


Figure 2. Graphical representation of the number of positive risk factors for each patient from the NICE head injury guidelines required for CS CT imaging



Discussion

This audit found that ED consultants were appropriately referring patients for CS CT scans based on the history, physical examination, and PF results. This is in compliance with the NICE clinical guidelines for the use of CS CT in the ED following CS injury.⁵

The literature has shown PF imaging to be inadequate for visualizing the complete CS in a large proportion of patients,³ which can lead to clinically significant fractures being missed.⁷ We found similar results in this audit with CS PF images insufficiently visualizing the complete CS in 44.4% of cases, with injuries at the cervical–thoracic junction most commonly missed. The literature in this area has found CT to be superior to PF imaging in the detection of CS injuries^{4,8} and 64-slice CT scans may be sufficient to safely clear significant CS injury.⁹ Recommendations have included the use of CT as an initial screening test in those with a very high risk of CS injury (patients with altered mental status or those requiring admission to the intensive care unit). However, CT may not be warranted in those

at low risk (minor trauma)^{4,8} due to negative consequences such as radiation exposure and cost.

CS CT scans deliver a significantly higher radiation dose in comparison to CS PF scans (26 mSv vs 4 mSv respectively).¹⁰ However, when a CT scan is justified by medical need, the associated diagnostic benefits outweigh the radiologic exposure risk.¹¹ In terms of cost efficiency to the hospital, CS PF is cheaper than CS CT scanning (US\$120 vs US\$329). However, once litigation costs were included for paralysis as a result of missed injury, the values were reversed (US\$2022 for CS PF compared with US\$553 for CS CT).¹² Antevil *et al.*¹⁰ also found that while the mean overall charges were greater for spinal CT imaging, there was a similar mean overall spinal imaging cost per patient.

A similar audit performed in New Zealand by Ball and Watson² assessed the appropriateness of CT imaging of the CS in the ED for intubated trauma patients. They found their management was also in accordance with the NICE head injury criteria, suggesting that guidelines may reduce time to definitive care. We agree with this statement since most patients reviewed in our ED also received prior PF imaging, which may have missed a definitive diagnosis picked up by CT and thus delayed treatment. Furthermore, the addition of

unnecessary PF scans would burden hospital resources, as patients have been found to spend more time in the radiology department for a CS PF scan in comparison with a CS CT,^{10,13} which could have been avoided had specific guidelines already been in place.

Additional guidelines have been documented in the literature to try and influence decision making in regard to the imaging modalities most relevant for diagnosis of injury. Kobaki *et al.*¹⁴ assessed the efficacy of Goergen's guidelines, which are widely used in Australia. They classify trauma patients into low, medium, or high risk, and identify the most appropriate imaging for each case. The authors found significance in the predictive power of Goergen's guidelines in detecting significant CS injury, which can rationalize the use of CT scanning only for patients who will benefit from it. Blackmore *et al.*¹⁵ used a fracture risk percentage intended to help influence CS imaging decision making at the initial patient presentation in the ED. To estimate the risk of CS fracture, a clinical prediction rule was used along with predictors including age, mechanism of injury, obvious head or facial injury, and loss of consciousness. With this, they found that CT is cost effective in moderate- to high-risk patients whose anticipated CS fracture risk was 4.2–11.2%.

Only patients who underwent a CS CT scan were selected for this audit, leading to a limitation involving the uncertainty of the proportion of patients who would have fulfilled the NICE criteria but were not imaged.

Conclusion

In this audit, 100% of patients fulfilled the NICE criteria for CS CT imaging following trauma to the CS. The literature shows that CS CT is overtaking CS PF imaging as the

primary modality of screening for suspected CS injuries due to its increased sensitivity, cost effectiveness, and time efficiency. EDs in the United Kingdom widely adopt the NICE head injury criteria but its use in Ireland is variable, with most EDs adopting local policies. It would therefore be beneficial for our ED and others alike to adopt guidelines regarding the use of CS CT imaging as an initial screening tool in suspected CS injuries.

Learning points

What is already known

- CS CT is overtaking PF imaging as the primary modality of choice for the imaging of head and neck injuries.
- The sensitivity of CS CT imaging is far greater than that of CS PF imaging.
- CS CT is more time efficient than CS PF.

What this study adds

- All patients sent for CS CT imaging in the ED fulfilled at least one criterion of the NICE guidelines for imaging of the CS following trauma.
- Adding to the literature, CS PF is inadequate for the complete visualization of the CS in a large proportion of cases.
- Having guidelines in place that specify which imaging technique is to be performed for CS trauma in the ED may reduce time to definitive care and hospital resources.

References

1. Como JJ, Diaz JJ, Dunham CM, Chiu WC, Duane TM, Capella JM, *et al.* Practice management guidelines for identification of cervical spine injuries following trauma: update from the eastern association for the surgery of trauma practice management guidelines committee. *J Trauma*. 2009 Sep;67(3):651-9. DOI: 10.1097/TA.0b013e3181ae583b.
2. Ball C, Watson D. A 12 month clinical audit of cervical spine imaging in multiply injured and intubated patients. *Br J Radiol*. 2010 Mar;83(987):257-60. DOI: 10.1259/bjr/53146076.
3. Gale S, Gracias V, Reilly P, Schwab CW. The inefficiency of plain radiography to evaluate the cervical spine after blunt trauma. *J Trauma*. 2005 Nov;59(5):1121-5.
4. Holmes JF, Akkinepalli R. Computed tomography versus plain radiography to screen for cervical spine injury: a meta-analysis. *J Trauma*. 2005 May;58(5):902-5.
5. National Institute for Health and Care Excellence. *Head Injury: Triage, Assessment, Investigation and Early Management of Head Injury in Children, Young People and Adults (CG176)*. London, UK: National Institute for Health and Care Excellence; January 2014.
6. Teasdale G, Jennett B. Assessment of coma and impaired consciousness: a practical scale. *Lancet*. 1974 Jul 13;2(7872):81-4. DOI: 10.1016/S0140-6736(74)91639-0.
7. Mathen R, Inaba K, Munera F, Teixeira PGR, Rivas L, McKenney M, *et al.* Prospective evaluation of multislice computed tomography versus plain radiographic cervical spine clearance in trauma patients. *J Trauma*. 2007 Jun;62(6):1427-31. DOI: 10.1097/01.ta.0000239813.78603.15.
8. Cain G, Shepardson J, Elliott V, Svensson J, Brennan P. Imaging suspected cervical spine injury: plain radiography or computed tomography? Systematic review. *Radiography*. 2010;16:68-77. DOI: <http://dx.doi.org/10.1016/j.radi.2009.09.001>.
9. Kanji HD, Neitzel A, Sekhon M, McCallum J, Griesdale DE. Sixty-four-slice computed tomographic scanner to clear traumatic cervical spine injury: systematic review of the literature. *J Crit Care*. 2014 Apr;29(2):314.e9-13. DOI: 10.1016/j.jcrc.2013.10.022.
10. Antevil JL, Sise MJ, Sack DI, Kidder B, Hopper A, Brown CVR. Spiral computed tomography for the initial evaluation of spine trauma: a new standard of care? *J Trauma*. 2006 Aug;61(2):382-7. DOI: 10.1097/01.ta.0000226154.38852.e6.
11. Brenner DJ, Hall EJ. Computed tomography — an increasing source of radiation exposure. *N Engl J Med*. 2007 Nov 29;357(22):2277-84. DOI: 10.1056/NEJMra072149.
12. Grogan EL, Morris JA, Dittus RS, Moore DE, Poulouse BK, Diaz JJ, *et al.* Cervical spine evaluation in urban trauma centers: lowering institutional costs and complications through helical CT scan. *J Am Coll Surg*. 2005 Feb;200(2):160-5. DOI: 10.1016/j.jamcollsurg.2004.10.019.
13. Daffner RH. Cervical radiography for trauma patients: a time effective technique? *AJR Am J Roentgenol*. 2000 Nov;175(5):1309-11.
14. Kokabi M, Raper DMS, Xing M, Giuffre BM. Application of imaging guidelines in patients with suspected cervical spine trauma: retrospective analysis and literature review. *Emerg Radiol*. 2011 Jan;18(1):31-8. DOI: 10.1007/s10140-010-0901-z.
15. Blackmore CC, Ramsey SD, Mann FA, Deyo RA. Cervical spine screening with CT in trauma patients: a cost-effectiveness analysis. *Radiology*. 1999 Jul;212(1):117-25. DOI: 10.1148/radiology.212.1.r99jl08117.