

RES MEDICA

Journal of the Royal Medical Society



Abdominal Crises III

I. R. S. Sinclair

F.R.C.S.

Abstract

The last of three articles written for Res Medica.

Acute Inflammatory Conditions

With the exception of the pancreas it is the hollow viscera which are involved in acute inflammatory disease. Always beginning as a localized process in the wall of the viscus the rapidity with which the inflammation spreads to the peritoneal space to produce peritonitis depends largely on the time taken for necrosis and perforation of the inflamed area to occur. If the reaction is slow, the inflamed area has often become adherent to adjacent structures or wrapped in omentum before perforation occurs so that even after this disaster the peritonitis remains localized for a further period and an abscess forms.

Copyright Royal Medical Society. All rights reserved. The copyright is retained by the author and the Royal Medical Society, except where explicitly otherwise stated. Scans have been produced by the Digital Imaging Unit at Edinburgh University Library. Res Medica is supported by the University of Edinburgh's Journal Hosting Service: <http://journals.ed.ac.uk>

ISSN: 2051-7580 (Online) ISSN: 0482-3206 (Print)

Res Medica is published by the Royal Medical Society, 5/5 Bristo Square, Edinburgh, EH8 9AL

Res Medica, Spring 1963, 3(3): 7-15

doi: [10.2218/resmedica.v3i3.394](https://doi.org/10.2218/resmedica.v3i3.394)

ABDOMINAL CRISES

By I. R. S. SINCLAIR, F.R.C.S.

The last of three articles written for Res Medica

ACUTE INFLAMMATORY CONDITIONS

With the exception of the pancreas it is the hollow viscera which are involved in acute inflammatory disease. Always beginning as a localized process in the wall of the viscus the rapidity with which the inflammation spreads to the peritoneal space to produce peritonitis depends largely on the time taken for necrosis and perforation of the inflamed area to occur. If the reaction is slow, the inflamed area has often become adherent to adjacent structures or wrapped in omentum before perforation occurs so that even after this disaster the peritonitis remains localized for a further period and an abscess forms.

Faced with the diagnostic problem of a patient who shows the features of general peritonitis it is sometimes impossible for the clinician, on physical signs alone, to decide in which part of the abdomen the trouble has arisen though a careful history will often give a strong lead. However, under the conditions prevailing in this country the patient is generally seen at a sufficiently early stage for some localizing signs to be present. It is convenient in practice to divide patients into those suspected of upper abdominal pathology and those whose clinical picture points to a lower abdominal or pelvic origin of the inflammation.

UPPER ABDOMINAL CONDITIONS.

Perforated Peptic Ulcer is the most dramatic of the common abdominal catastrophes. Though the well-known symptoms and signs of peptic inflammation may have been present for many months or years this is not invariably so. Because the commonest sites of peptic ulceration are separated from the anterior abdominal wall only by the liver edge and lie high above the great omental apron the possibility of sealing off the inflamed area by omental or peritoneal adhesions is limited; perforation is usually free and involvement of the anterior parietal peritoneum immediate. Therefore, though occasionally a small leak of gastric juice may produce a localized reaction and a clinical picture suggestive of an acute exacerbation of ulcer dyspepsia, much more commonly the period of localization to the upper abdomen is short or even non-existent. The dramatic onset, the unremitting severity of the pain which freezes the patient into immobility, afraid even to breathe, and the intense reflex contraction of the anterior abdominal muscles usually makes diagnosis easy in a patient with a history of ulcer dyspepsia. Apart from the very small leak, confusion arises in those rare cases of perforation of a gastric ulcer into the lesser peritoneal sac which confines the reaction to that deep cavity remote from the anterior parietes and the examiner's hand. In cases of doubt a plain x-ray of the abdomen taken with the patient in the upright position will

often confirm the presence of a perforation by demonstrating free gas beneath the diaphragm. This preliminary film is also of value in revealing inflammatory changes in the lungs in a high proportion of cases of perforation. Already present on admission due to the restricted ventilation caused by pain, these changes have in the past been erroneously labelled as post-operative complications.

With few exceptions the safest method of treatment of a perforated peptic ulcer is by immediate operation. When there is only a small localized leak, in the aged or where other complications exist, expectant treatment by continuous gastric suction and intravenous fluid therapy may be preferred but is a method requiring constant vigilance and carrying a significant risk of failure. Whether the surgeon decides to carry out simple suture of the perforation or to perform some type of gastrectomy with removal of the ulcer, depends partly on technical considerations (it may be impossible to suture or plug a large gastric perforation) partly on the condition of the patient and not least on the experience of the operator. In the fit subject the risks of gastric resection in the first few hours after perforation are no greater than those of simple closure of the perforation, given expert surgery and anaesthesia, and in patients with a long history of dyspepsia or with previous complications a second operation may thus be avoided.

Acute Cholecystitis and Cholangitis. Acute inflammation in the gall bladder produces great tension at an early stage, because the infective process is nearly always due to stagnation as a result of calculous obstruction of the neck of the gall bladder. Acute symptoms arise long before perforation occurs and localizing symptoms and signs are correspondingly prolonged. For this reason diagnosis is often relatively easy. A tensely distended inflamed gall bladder may project beyond the liver margin if previous chronic inflammation has not produced fibrous thickening and contracture of its wall—so-called empyema of the gall bladder—but muscular guarding and rigidity often prevent its recognition on examination. General peritonitis is rare but some degree of peritoneal reaction is usual and may result in a trickle of inflammatory exudate down the right side of the abdomen. In this event tenderness may be quite marked in the right iliac fossa.

Although the management of acute cholecystitis is usually conservative, urgent reappraisal is called for should the pain and local signs persist or increase after forty-eight hours. This may mean that the gall bladder wall has become gangrenous or, especially in elderly patients with a palpable mass, that the gall bladder has undergone torsion. Where pain in the right iliac fossa makes the exclusion of acute appendicitis impossible, it is much better to do an immediate cholecystectomy than to risk leaving a gangrenous gall bladder.

Acute cholecystitis is rarely accompanied by a significant degree of jaundice but from time to time one encounters a patient whose symptoms and signs, otherwise suggestive of cholecystitis, are accompanied by jaundice and rigors. The triad of pain, jaundice and rigor, known for the past century as Charcot's biliary fever, indicate a diagnosis of infective cholangitis secondary to a partial obstruction of the common bile duct. Untreated, or wrongly treated by antibiotic therapy without surgical drainage, such patients may progress to develop multiple liver abscesses or to die from what has loosely been called the "hepato-renal syndrome." Deaths from acute renal failure in patients with biliary disease have been recorded intermittently over many years and much has been written on the possible association between the two systems. Recently somewhat discredited, I believe this syndrome to be a real and important entity and have encountered it on a number of occasions during

the past three years in the artificial kidney unit at the Royal Infirmary. In each case acute renal failure developed in a patient with infective cholangitis and in every one the renal failure persisted and blood cultures continued to yield coliform bacilli until surgical drainage of the biliary tree was carried out. Recent experimental work on the effect of coliform endotoxins on renal blood flow may shed light on the fundamental nature of the syndrome.

Acute Pancreatitis. This condition is not so rare as many believe. If it is sought, it will be found nearly as commonly in this country as in North America or Scandinavia despite the virtual absence of the alcoholics who comprise a large proportion of cases of pancreatitis in these two areas. Many theories and much experimental research has left the causation of the condition still uncertain. The finding of biliary calculi in 50 per cent. of cases of acute pancreatitis does not necessarily imply a causative relationship and Opie's (1902) much quoted finding of a gallstone impacted at the ampulla of Vater in a fatal case of acute pancreatitis is exceptional. On the other hand anatomical studies in fatal cases have revealed a potential common channel between the biliary and pancreatic ducts at their lower ends in almost all cases and this, together with much experimental evidence, suggests that biliary reflux, perhaps due to spasm or oedema at the ampulla during a phase of secretory activity following a meal or the consumption of alcohol, is a likely explanation in many cases. Obstruction of the actively secreting gland, even in the absence of biliary reflux causes pancreatitis in dogs and the definite hazard of injury to the pancreas or to its major ducts during gastroduodenal surgery explains why post-operative pancreatitis is today one of the principal early complications of gastric resection. There is no evidence that primary bacterial infection is ever responsible for pancreatitis but oedematous or subsacute pancreatitis is a well-known complication of mumps and it may be that the oft-maligned diagnosis of "abdominal influenza" is sometimes justifiable and describes a similar entity. During the past few years experimental evidence has been put forward to support the view that either a sensitivity reaction to foreign (bacterial) protein or a vascular occlusion may explain most cases of acute pancreatitis but the evidence for these views is not yet sufficient to command general acceptance.

Certain diagnosis of acute pancreatitis is often impossible prior to laparotomy. In its most acute form the sudden onset and signs of peritonitis may simulate the clinical picture of a perforation but more often the deep retroperitoneal situation of the pancreas prevents early involvement of the anterior parietal peritoneum so that there is tenderness rather than rigidity and back pain is very common. Proximity to the pylorus and to the sympathetic plexuses causes pylorospasm with reflex retching and vomiting and early paralytic ileus. The amount of fluid exudate which can be lost into the loose retro-peritoneal and mesenteric tissue planes is much greater than is often realized and this cause of hypovolaemia rather than any esoteric form of trypsin shock probably accounts for the profound hypotension which is occasionally found in very severe cases.

Estimation of the serum amylase level is sometimes of great help in clinching the diagnosis but too much reliance must not be placed on this test. Abnormally high levels may last for only a few hours and comparable levels may also be found in other acute upper abdominal conditions, notably perforation of a peptic ulcer. Radiological examination to exclude the presence of free gas under the diaphragm is always a wise precaution before the diagnosis of acute pancreatitis is accepted. At laparotomy the diagnosis is usually apparent from the oedematous and often bile-stained tissues around the duodenum and pancreas and from the flecks of white saponified fat in the omentum and mesenteries even before the pancreas itself is examined but even the operative

findings may be misinterpreted. A few weeks ago I encountered a patient in whom the dramatic onset of excruciating pain with intermittent exacerbations accompanied by reflex retching and a tender but not rigid abdomen led to a tentative diagnosis of internal strangulation or torsion. At laparotomy the whole small bowel was cyanosed and the mesenteric vessels non-pulsatile. The diagnosis of mesenteric vascular thrombosis was disproved at autopsy two days later when it was found that the oedematous and necrotic pancreas had obstructed the superior mesenteric vascular pedicle as it traversed the groove between the body of the gland and the uncinate process.

So long as the causation remains in doubt treatment must be based on the general principles of combating hypovolaemic shock and of resting the inflamed gland by continuous gastric suction to prevent the access of gastric acid into the duodenum and by autonomic blocking drugs to inhibit the neurogenic component of pancreatic secretion. Provided the diagnosis can be made with certainty immediate operation is not desirable but if, as is usually the case, the diagnosis is only substantiated at laparotomy surgical decompression of the biliary tree is rational if there is evidence of biliary obstruction. Drainage of the peritoneal cavity has nothing to offer in the early case in contrast to the later stages when drainage of a pancreatic abscess or of a pseudo-cyst may be life saving. The vogue for administration of steroids has little factual evidence to support it and the use of the trypsin and kallikrein inhibitor "Trasylof", much vaunted in Europe during the past two years has so far been unimpressive in my hands. Because secondary infection may develop in the devitalized pancreas it has been customary to give a broad spectrum antibiotic from the time of admission to hospital and this practice certainly reduces the mortality of experimental pancreatitis in dogs. However, the liability of dogs to develop serious infective complications of diverse abdominal catastrophes is incomparably greater than that of man and having regard to our present hospital bacterial environment and the grave risks of injudicious and uncontrolled antibiotic therapy it may be wiser to withhold such treatment until definite evidence of bacterial infection appears. On the theory that the rapid disintegration of the pancreatic tissue is due to auto-digestion by non-specific intracellular enzymes rather than by the specific enzymes which these cells secrete and in view of the very high metabolic rate of pancreatic tissue, attempts have been made in recent years to arrest the progress of acute pancreatitis by the administration of thiouracil and have been reported to yield dramatic results. I have no personal experience of this method.

LOWER ABDOMINAL CONDITIONS

Acute Appendicitis. Turning to the lower abdomen we come to the commonest of all acute abdominal emergencies. It was Sir David Wilkie who first stressed the different natural history of the primarily catarrhal appendicitis and the primarily obstructive type of disease. The former, which is much less common, may often subside spontaneously whereas the latter almost invariably proceeds to gangrene and perforation unless the appendix is removed surgically.

Pain from an inflamed or obstructed appendix is usually felt for some hours only in the general area of reference of mid gut derivatives, namely the central abdomen, and, especially in obstructive appendicitis, the pain is colicky so that simple gastro-enteritis or indigestion is suspected. At this time, during which one or two episodes of reflex vomiting are common, tenderness will be present over the appendix itself, but it is only when the parietal peritoneum is involved by a spread of the inflammatory exudate that the patient experiences spontaneous pain over the appendix. This classical sequence of events makes the diagnosis very easy in the typical case but unfortunately few cases

are typical. In general, there is only slight pyrexia and the pulse rate, which is normal in the early stages, soon rises to a disproportionate extent, whereas in acute pyelonephritis, which may be suspected if urinary symptoms result from proximity of the appendix to the ureter or bladder, the temperature is usually much higher in relation to the pulse rate, and rigors are more common. In pyelonephritis loin pain is usual and the absence of rebound tenderness and crossed tenderness (Rovsing's Sign) help to exclude intraperitoneal inflammation. Certain other manoeuvres such as stretching the psoas muscle (by hyper-extension of the hip) or the obturator internus (by medially rotating the hip) sometimes help to confirm a diagnosis of appendicitis in doubtful cases, the production of pain indicating an inflammatory reaction in proximity to these muscles. The importance of a rectal examination, especially when the appendix lies in the pelvis, remote from a hand palpating the abdomen above it, was stressed in the first article of this series, where other pitfalls in diagnosis were also discussed. The high retrocaecal or paracolic appendix may simulate gall bladder disease, and, especially in the elderly, a retro-ileal appendix may present minimal signs in the early stages, later simulating a subacute intestinal obstruction with distension and fluid levels on x-ray examination. Early diagnosis is always important but it is particularly vital in the child, whose omentum has not yet grown sufficiently to reach and wrap around an inflamed appendix, and in the elderly whose reaction and resistance are low. In these two groups the progress to generalized peritonitis is rapid and it is in these that most of the fatalities are still found.

In general, the correct management of acute appendicitis is immediate appendicectomy, whether the condition is diagnosed after two hours or several days. Only if a palpable mass indicates that nature has already succeeded in localizing the infection is conservatism justified. With rest and antibiotics such cases usually subside. If not, simple drainage of the abscess is all that is advisable. Whether or not drainage is needed at this stage, interval appendicectomy should always be carried out some two or three months later when the reaction has settled. In every conservatively treated patient over the age of forty a barium enema should be carried out as soon as the acute symptoms have settled. The precipitation of acute obstructive appendicitis by a tumor of the caecum is well recognized and it is tragic deliberately to defer operation on a caecal carcinoma for three months just because it has presented as a case of right iliac fossa pain with a palpable mass.

Acute Diverticulitis. Diverticula of the colon are so common that diverticulitis and its complications are one of the most frequent causes of lower abdominal peritonitis. Occurring most often in the pelvic colon, the clinical picture of diverticulitis has been described as left sided appendicitis. This is not a very accurate analogy as the type of patient is different—usually obese, constipated and elderly—the central pain of mid gut disease is absent and the progress is generally slower, a pericolic abscess being much commoner than general peritonitis in the untreated case. Treatment is at first conservative, with dietary restrictions and antibiotics. Only if symptoms fail to subside or if colonic obstruction or, occasionally, melaena, complicates the situation is operation carried out. In the presence of marked pericolic inflammation and adhesions the diseased segment of bowel is left untouched and a proximal (transverse) colostomy is fashioned to divert the faecal stream and allow the infection to subside. Resection of the diseased segment can then be carried out as an elective procedure before the colostomy is closed.

GYNAECOLOGICAL EMERGENCIES

Acute Salpingitis must always be considered in cases of lower abdominal peritonitis in women. The frequent onset at the time of a menstrual period,

the presence of vaginal discharge, the bilateral tenderness and, if a tubo-ovarian abscess has formed, the presence of a palpable pelvic mass all suggest the correct diagnosis. The infection is usually of low virulence and responds to conservative treatment. Operation is therefore avoided unless acute appendicitis cannot be excluded.

Lower abdominal inflammatory conditions are sometimes simulated by *rupture of a Graafian follicle*. The patient is usually a young woman and the symptoms tend to occur around the middle of the menstrual cycle. The pain starts in the lower abdomen and as a rule is a constant dull ache unaccompanied by vomiting. Laparotomy is usually undertaken on the presumptive diagnosis of acute appendicitis.

Rupture of an ovarian cyst may also give rise to a picture of pelvic peritonitis or of intraperitoneal bleeding. *Haemorrhage into an ovarian cyst* causes severe, continuous, increasingly lower, abdominal pain accompanied by tenderness and rigidity but, despite the muscle spasm, it is usually possible to feel a large, tense spherical swelling. *Torsion of an ovarian cyst* on its pedicle results in a more dramatic onset of severe pain, often varying in intensity and accompanied by reflex vomiting, suggesting some form of internal strangulation. All these conditions require operative treatment.

Ectopic Gestation. Tubal pregnancy may present as an abdominal emergency in several ways of which the most important are either a slow intraperitoneal leak of blood simulating a pelvic peritonitis or a massive intraperitoneal haemorrhage in which the signs of general peritonitis rapidly appear accompanied by pallor and hypotension. There is a history of recently absent or abnormal menstrual bleeding in almost every case but there is no characteristic type of irregularity. Complete amenorrhoea followed by bleeding is the most common sequence of events. Even with the slow intraperitoneal leak it is remarkable how often pain is experienced in the left shoulder and the patient should always be specifically asked about pain in any sites other than the abdomen. A history of fainting is also very suggestive of intraperitoneal haemorrhage. Blood in the peritoneal cavity acts as an irritant and usually causes fever and leucocytosis as well as stimulating bowel contractions which, by giving rise to intestinal colic, may confuse the diagnosis. Colicky pain may also result from uterine contractions.

Although it may sometimes be possible to palpate a mass in either iliac fossa it is the vaginal examination which is most important. The softened cervix, the palpation of a tender, boggy, mass in the Pouch of Douglas and often the trace of blood on the examining finger will confirm the diagnosis.

In cases with massive bleeding there is no time for close interrogation or prolonged examination. A glance at the pallid, clammy, restless woman is enough to suggest haemorrhage as the cause of the abdominal pain and during the child-bearing years the most likely source for this lies in the pelvis. Such patients are the most urgent of all abdominal emergencies. Infusion of dextran or plasma is followed by whole blood transfusion as soon as possible but in desperate cases laparotomy to control the bleeding may be necessary before resuscitation is possible.

VASCULAR EMERGENCIES

INTRAPERITONEAL HAEMORRHAGE

Spontaneous intraperitoneal bleeding may arise from many different sources. In young women a ruptured ectopic gestation is the most important cause (see above). *Rupture of an aneurysm of the splenic artery* is another vascular disaster which is not only much commoner in females than in males but is encountered very often in the later months of pregnancy. The most common pathological basis is atheromatous degeneration with mycotic

aneurysm in association with bacterial endocarditis coming second. Although sudden massive haemorrhage may be the first sign of trouble the initial rupture is often to some extent controlled by the formation of a false aneurysm in the retroperitoneal tissues around the hilum of the spleen or in the lesser sac and rupture into the general peritoneal cavity occurs after a delay of hours or even days. In such cases the early clinical picture may simulate some upper abdominal inflammatory crisis such as perforation of a peptic ulcer into the lesser sac or acute pancreatitis. Though rare, the diagnosis of this emergency is of great importance because delay in operative treatment is almost certain to be fatal and, if full advantage is to be taken of the period of grace given by a preliminary leak the condition must always be kept in mind in a woman who develops acute upper abdominal symptoms during the last trimester of pregnancy. Operative treatment is itself a matter of considerable hazard. The gravid uterus make proper exploration of the posterior abdominal structures impossible and, as the foetus is always dead, rapid caesarean section may be necessary despite the added risk in a critically ill patient. Even then, the infiltration of the tissues with blood makes identification of the source of bleeding extremely difficult.

Spontaneous rupture of the spleen occurs usually in the presence of splenic disease though it has occasionally occurred in a normal spleen in the last month of pregnancy or during parturition. In the tropics the most frequent cause is malarial enlargement but in this country glandular fever and leukaemia are the usual diseases.

Spontaneous rupture of minute congenital aneurysms probably accounts for those occasional cases of "abdominal apoplexy" in which a bleeding point is not detected at laparotomy or autopsy. Over the past fifteen years I have operated on three patients who presented as cases of general peritonitis only to find the peritoneal cavity full of blood which proved to be arising from a renal carcinoma. In each case the assumption that the haemorrhage indicated an advanced and inoperable malignancy was disproved at the post-mortem examination which showed the blood to be coming from distended normal veins and not from the tumour. The kidney was technically removable and in none of the three cases were there evident metastases. It would therefore seem reasonable to carry out a trans-abdominal nephrectomy in these circumstances as being the only way to arrest the bleeding and at the same time offer a reasonable prospect of cure. Why these distended veins should have ruptured is not clear. The obvious explanation that the tumour, as its wont, had grown into and obstructed the renal vein did not hold good in any of my three cases.

RETROPERITONEAL HAEMORRHAGE

In an elderly patient the most likely cause of severe intra-abdominal haemorrhage is *rupture of an atherosclerotic aortic aneurysm*. Rupture into the general peritoneal cavity is rare, most cases showing a very extensive retroperitoneal extravasation. As with other types of bleeding it is surprising how often the haemorrhage takes the form of a small preliminary leak which is temporarily controlled by the tension in the surrounding tissues and by clotting. The acute onset of sudden severe constant abdominal pain, often radiating to the back or legs may not be accompanied by obvious signs of blood loss until the final catastrophic rupture takes place. Generalized tenderness may prevent adequate palpation so that the presence of a pulsatile mass is easily missed especially in an obese patient. A bruit is rarely recognisable on auscultation after an aneurysm has ruptured—especially if hypotension is marked. Progressive distension due to ileus caused by the retroperitoneal haematoma coupled with reflex vomiting may simulate the picture of acute

intestinal obstruction with internal strangulation. The distended bowel may also obscure the radiographic shadows of calcification in the wall of the aneurysmal sac but x-ray examination should never be omitted. Although a past history of recurrent back or abdominal pain (the latter sometimes in the form of colicky pains during digestive activity—that so-called “abdominal claudication”) is a useful pointer, such a history is obtained from less than half of the patients. Conversely, when abdominal or back pain is caused by an aortic aneurysm the situation is one of some urgency for the onset of symptoms rarely precedes rupture of the aneurysm by many months. The only treatment carrying any chance of success is resection of the aorta and its replacement by a homograft or woven prosthesis—a long and dangerous procedure under difficult conditions when rupture has occurred.

Retroperitoneal haemorrhage is not uncommon in haemophilia and should always be kept in mind when a known haemophilic presents with symptoms and signs of an abdominal emergency, especially if a tender mass is palpable. This is the only circumstance in which laparotomy is to be avoided in cases of suspected intra-abdominal haemorrhage.

ACUTE GASTRO-INTESTINAL HAEMORRHAGE

By far the commonest condition causing acute gastro-intestinal bleeding is peptic ulceration (about 85 per cent.) with gastric erosions and portal hypertension tying for a very poor second (about 5 per cent). The remaining 10 per cent. of cases is made up of a variety of conditions such as hiatus hernia, gastric tumours, peptic ulcer in a Meckel's Diverticulum, angiomas, ulcerative colitis, diverticulitis, blood dyscrasias and aneurysmal rupture into the alimentary tract.

The role of surgery in cases of *bleeding peptic ulcer* has undergone a revolutionary change during the past fifteen years. It is now recognised that early operation is essential if safety is to be achieved and the accumulation of data from large series of cases has taught us that the patient with a known ulcer, who is over 40 years of age and who has either a previous episode of bleeding (or perforation) or who suffers a second haemorrhage after admission to hospital is best treated by immediate operation. Indeed, the older the patient the less well is blood loss tolerated and the sooner should operation be carried out. There is little evidence that adequate blood replacement adds to the risk of further bleeding and it is still too common to leave a patient hypovolaemic or even hypotensive for many hours, with the risk of vascular thrombosis or acute renal failure.

The importance of recognizing acute haemorrhage in *portal hypertension* lies more in the need to avoid than in the necessity to carry out urgent operation. Haemorrhage from oesophageal varices tends to be self-limiting and major surgery is ill-tolerated in patients with severe liver damage. The haematemesis is usually severe, with vomiting of red blood and a history of ulcer dyspepsia may be absent.

To assist in accurate pre-operative diagnosis of doubtful cases emergency contrast radiography using the water-soluble medium “gastro-grafin” has proved of great value and as a last court of appeal before surgery oesophagoscopy may reveal blood welling up from below the cardia and thus exclude oesophageal varices as a cause. The recent advent of the flexible fiberoptic may increase the value of emergency endoscopy in the differential diagnosis of gastro-duodenal bleeding. The use of a Sengstaken* tube to produce traction tamponade on the lower oesophagus will, of course, show whether the bleeding is coming from oesophageal varices or from below and this method of pressure control of bleeding varices may be continued for periods of up to forty-eight hours.

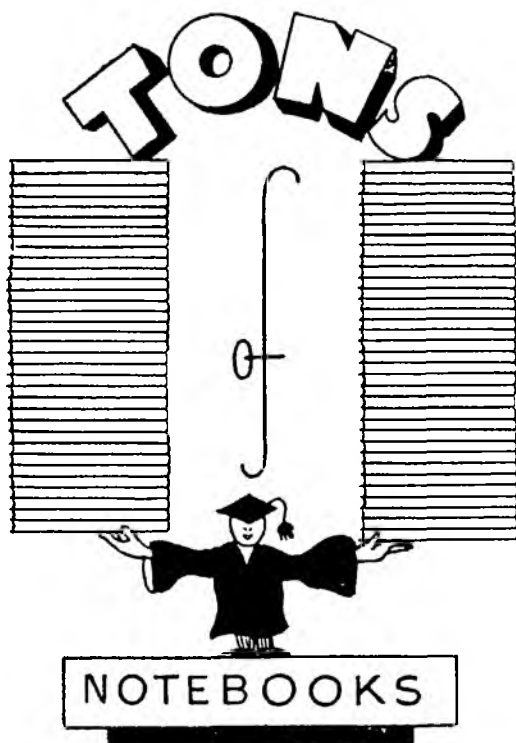
Intravenous infusion of pituitrin will significantly lower the portal pressure by causing splanchnic vasoconstriction and this simple procedure is well worth trying in the acute phase. The possibility of a prothrombin deficiency due to the underlying liver disease must be remembered and intravenous Vitamin K. should be given. Once immediate control of bleeding has been achieved the question of elective porto-caval anastomosis can be considered. In the intervening days the risk of hepatic coma from absorption of protein from the blood-filled gut is very real in cases of hepatic disease and purgation to eliminate the blood coupled with antibiotic therapy restrict bacterial activity are an integral part of the treatment.

In this necessarily sketchy and incomplete review of abdominal emergencies the emphasis has been laid on diagnosis and I have written of the rarities as well as of the common place.

If we see a bird on a tree the chances are, of course, that it is a sparrow, not a canary. Yet it is just for this reason that we remember the solitary canary when we have forgotten the multitude of sparrows. This is no bad thing. Recognition of the sparrows among the abdominal crises is our daily task and, well done, saves many lives, but to recognize the canaries adds that spice which sustains our enthusiasm and stimulates our senses.

When dealing with abdominal emergencies time is not on the side of our patients, though it may make things more obvious for us. Delay can be fatal, and, in the words of Francis Bacon "There is surely no greater wisdom than well to time the beginning and onset of things."

*(A triple lumen tube carrying two balloons. The distal spherical balloon is inflated in the stomach and traction applied to pull the balloon back against the cardia. The proximal elongated balloon is then inflated within the lower oesophagus.)



BROWN

OF THE

MOUND

STATIONERS
and PRINTERS

**NORTH BANK STREET
EDINBURGH**

Telephone CAL 5960
