

RES MEDICA

Journal of the Royal Medical Society



Probing Fistulae in the G.I. Tract

Paul J. Jenkins

Medical Student, University of Edinburgh

Pradip K. Datta

Consultant Surgeon, Caithness General Hospital

Abstract

Fistulae are commonly encountered in general surgery. A fistula is an abnormal connection between two epithelial surfaces (figure 1). It can connect two hollow viscera together, or can connect a hollow viscus to the skin. In this way they can either be visceral and internal, or cutaneous and external. The connection between the surfaces is usually lined with granulation tissue. A sinus is a granulating track from a source of infection to the surface. Sinuses can develop into fistulae if inadequately treated.

Copyright Royal Medical Society. All rights reserved. The copyright is retained by the author and the Royal Medical Society, except where explicitly otherwise stated. Scans have been produced by the Digital Imaging Unit at Edinburgh University Library. Res Medica is supported by the University of Edinburgh's Journal Hosting Service url: <http://journals.ed.ac.uk>

ISSN: 2051-7580 (Online) ISSN: ISSN 0482-3206 (Print)

Res Medica is published by the Royal Medical Society, 5/5 Bristo Square, Edinburgh, EH8 9AL

Res Medica, Summer 2003 : 16-19

doi:[10.2218/resmedica.v0i0.1008](https://doi.org/10.2218/resmedica.v0i0.1008)

Probing Fistulae in the G.I. Tract

Paul J Jenkins, Medical Student, University of Edinburgh

Pradip K Datta, Consultant Surgeon, Caithness General Hospital

Introduction

Fistulae are commonly encountered in general surgery. A fistula is an abnormal connection between two epithelial surfaces (figure 1). It can connect two hollow viscera together, or can connect a hollow viscus to the skin. In this way they can either be visceral and internal, or cutaneous and external. The connection between the surfaces is usually lined with granulation tissue.

A sinus is a granulating track from a source of infection to the surface. Sinuses can develop into fistulae if inadequately treated.

A fistula occurs as a complication of many different diseases, and from a variety of causes:

- Congenital - tracheo-oesophageal fistula
- Acquired
 - traumatic, e.g. rectovaginal fistula following labour
 - neoplastic - carcinoma
 - inflammatory - Crohn's Disease
 - infective - diverticulitis
 - fistula-in-ano
 - iatrogenic - surgical (post-op)
 - radiation

"A fistula is an abnormal connection between two epithelial surfaces. It can connect two hollow viscera together, or can connect an hollow viscus to the skin. Gastro-intestinal fistulae are a surgical challenge."

Tracheo-Oesophageal Fistula

Tracheo-oesophageal fistula is most commonly found with oesophageal atresia as a **congenital abnormality**. It results from incomplete separation of the larynx and trachea from primitive foregut. In 85% of cases the upper end of the oesophagus ends in a blind sac. The upper end of the lower portion of the oesophagus commu-

nicates with the trachea at the level of T4. In 50% of cases there has been maternal hydramnios, and in many cases there are other congenital malformations.

Babies with this condition suffer cyanosis, choking and feeding problems.

Regurgitation from the blind oesophageal sac leads to aspiration and pneumonia. This condition is distinguished from obstruction by the presence of choking rather than vomiting. Confirmation of the diagnosis is obtained by the failure to pass a soft catheter. Opaque x-ray contrast medium injected through the catheter shows the sac.

Emergency surgery is necessary within 24 hours

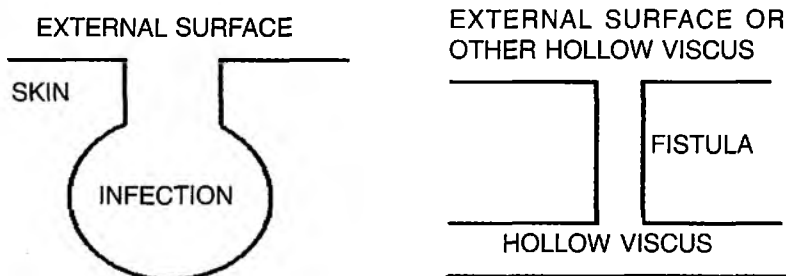


Figure 1. Examples of fistulae

to disconnect the oesophagus from the trachea and perform an end to end anastomosis with the free end of the oesophagus. In expert centres mortality is less than 10%.

In older patients, tracheo-oesophageal fistulae most commonly occurs in advanced **carcinoma of the oesophagus**. The tumour erodes the trachea. The condition should be obvious when a patient with dysphagia complains of severe coughing episodes on trying to swallow any food. This leads to aspiration pneumonia. The original diagnosis is confirmed by upper GI endoscopy which is followed by bronchoscopy.

Treatment is of the underlying condition. In very advanced disease the palliative insertion of a stent is the treatment of choice.

Abdomen

Gastrojejunalocolic fistulae most commonly arise from a carcinoma of the stomach eroding into the transverse colon or vice-versa. This results in severe diarrhoea, foul gas being discharged, and the vomiting of formed faeces. Other symptoms of gastric carcinoma are present such as anaemia, asthenia and cachexia. The onset is extremely rapid.

Gastrojejunalocolic fistulae are also a complication of posterior retrocolic gastro-jejunosomy, and may also occur from chronic anastomotic peptic ulceration.

Anastomotic fistulae are usually cutaneous and present with bowel contents discharging through the wound several days post-operatively.

Pancreatic fistulae (cutaneous) commonly occur after operation on the pancreas for trauma, after Whipple's or after pancreatic necrosectomy for severe acute pancreatitis and external drainage of a pseudocyst. The pancreas can enter a hypersecretory mode and can secrete as much as 2 litre of juice per day. Therefore, close attention must be paid to fluid balance in such patients. The patient should undergo an ultrasound scan to ensure there are no pancreatic fluid collections, but otherwise should heal rapidly. If the pancreatic duct has been disrupted,

then distal pancreatectomy should be undertaken.

Aortoduodenal fistula is an uncommon complication of abdominal aortic aneurysm surgery. Patients commonly present months or years after operation with haematemesis or melaena. Urgent operation should be carried out to separate the duodenum from the graft, close any holes in the duodenum and remove the graft.

Crohn's Disease is a major cause of intestinal fistulae. It causes granulomatous transmural inflammation followed by axillo-inflammatory bifemoral graft. Approximately 25% of patients develop fistulae at some point, the anus being a common area. Crohn's presents with chronic diarrhoea, abdominal pain, weight loss and a spectrum of extra-abdominal symptoms. Fistulae are external or internal. External can be enterocutaneous or perianal. Internal fistulae are enteroenteric, enterocolic, enterovaginal and enterovesical. Confirmation of fistulae can be demonstrated with contrast studies. Abscesses must be drained and enterocutaneous fistula can result from Crohn's disease through the same mechanism. Treatment depends on the level of the fistula. Those with low output (<1 litre/day) will heal by secondary intention. Those with high output must be surgically repaired with excision of the affected bowel loop. Steps must be taken

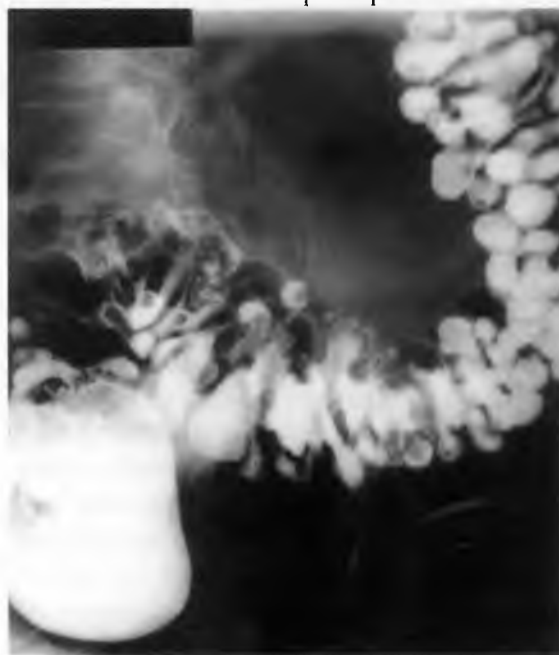

Figure 2. Barium enema showing severe diverticular disease

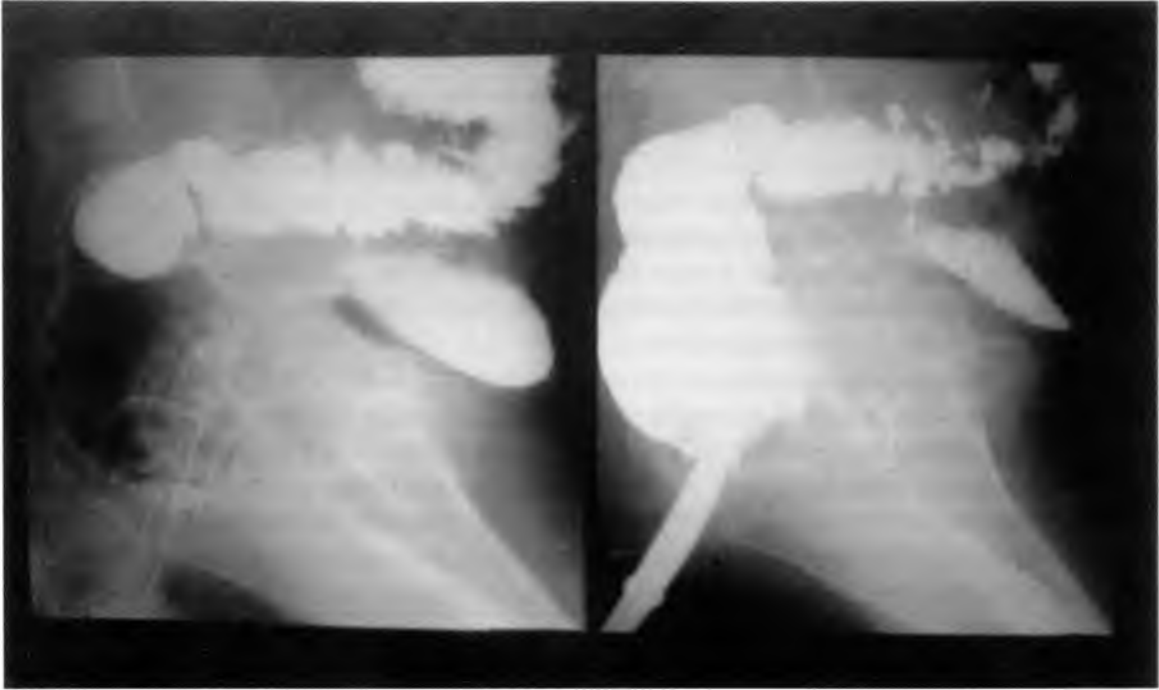


Figure 3. Lateral view of a barium enema, showing a vesicocolic fistula

to protect the surrounding skin from intestinal juices.

Diverticulitis is a condition with recurrent infection of diverticula in the wall of the colon (figure 2). These can form into pericolic abscesses. Rupture can occur into the peritoneal cavity. Alternatively, adherence of the inflamed colon to adjacent organs may result in fistulae between the colon, bladder, small bowel, skin or vagina. Fistulae occur in 2% of patients with diverticular disease, but are much more common in severe disease. Fistulae are present in 20% of patients requiring operative treatment. A history of recurrent left iliac fossa pain, with a swinging fever and leukocytosis, along with symptoms and signs of fistulation should point to diverticulitis as the cause of fistulation. Vesicocolic fistulae occurring through diverticular disease are tend to result in pneumaturia, whereas though arising through neoplasia more often give rise to faecaluria. Treatment of diverticulitis is with fluids and antibiotics (Metronidazole and Gentamycin), with drainage of any intra-abdominal abscesses.

Vesicocolic fistulae (figures 3 & 4) are most commonly found in Crohn's disease, diverticulitis and colonic carcinoma. This results in in-

tractable cystitis and pneumaturia. Investigation is with MSU, barium enema, sigmoidoscopy, colonoscopy and cystoscopy. Intra-venous urography should be carried out to rule out obstruction or fistulae higher up the urinary tract.

Treatment is by laparotomy, with excision of the affected bowel loop, anastomosis, and repair of the bladder wall.

Fistula-in-Ano results from the rupture of anal subcutaneous and submucosal abscesses. These abscesses arise within glands in the anal wall and spread along tissue planes. They are inadequately treated by incision and drainage alone. The abscess may spread to the skin as a sinus with chronic discharge of pus. The sinus eventually will communicate with the anal canal higher up. Such fistulation occurs in 30% of abscess. An internal opening in the anal canal communicates with one or more openings in the perianal skin. The internal opening of the fistula may be felt on rectal examination. Fistulae are classified by their level and the structures of the anal canal they traverse. They are classified as subcutaneous, submucous, low anal, high anal, ano-rectal, and pelvirectal. Those entirely beneath the ano-rectal ring can be treated by the insertion of a probe, and incising down onto the probe to lay

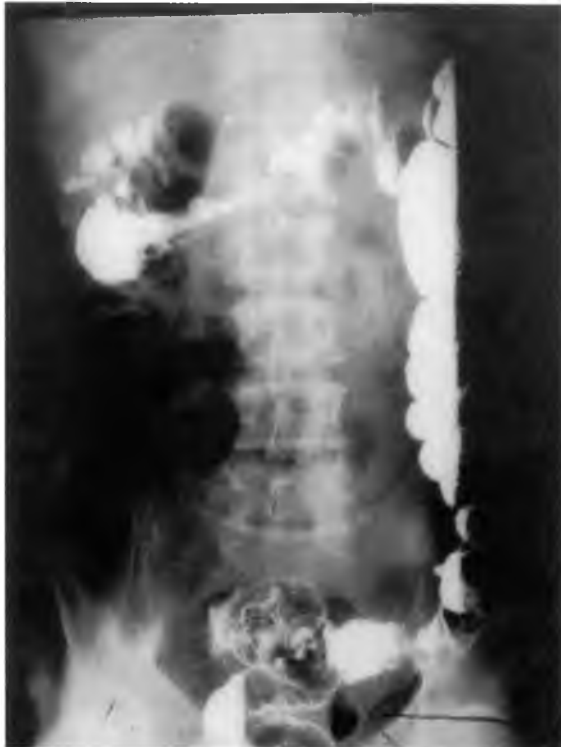

Figure 4. Barium enema showing air in urinary bladder

open the fistula. The track is then laid open and left to heal by secondary intention. This has no effect on faecal continence as the external sphincter remains intact. In higher fistulae, the track can only be opened to the ano-rectal ring. A ligature is thus passed through the upper track and left for 2 to 3 weeks for scar tissue to form.

Goodsall's Rule is useful if the location of the internal opening is not obvious. "If the external opening lies anterior to a line drawn transversely through the centre of the anus, the tract passes radially through a straight line towards the internal opening. If the external opening is posterior to the line, the track curves in a horseshoe manner to open into the midline posteriorly".

Gastro-intestinal fistulae are a surgical challenge. The best outcome is obtained by a multi-disciplinary approach between the surgeon and the gastroenterologist with help from the radiologist for diagnosis and the dietician for overall management.

Bibliography.

- Wakelin SJ, Crofts TJ.** Gastroduodenal disorders. In Garden OJ et al eds. Principles and Practice of Surgery, pp239-61. Edinburgh: Churchill Livingstone, 2002. Ref ID 434. Reprint: Not in file.
- Garden OJ.** The Pancreas. In Garden OJ et al eds. Principles and Practice of Surgery, pp262-91. Edinburgh: Churchill Livingstone, 2002. Ref ID 435. Reprint: Not in file.
- Dunlop MG.** Intestine and Appendix. In Garden OJ et al eds. Principles and Practice of Surgery, pp318-49. Edinburgh: Churchill Livingstone, 2002. Ref ID 436. Reprint: Not in file.
- Dunlop MG.** Anorectal Conditions. In Garden OJ et al eds. Principles and Practice of Surgery, pp350-67. Edinburgh: Churchill Livingstone, 2002. Ref ID 437. Reprint: Not in file.
- Colonic Diverticular Disease.** Current Problems in Surgery 2000; 37: 463-508. Ref ID 438. Reprint: Not in file.

An engraving entitled: "Melbourne Place and Victoria Terrace from George IV Bridge"

Matthew H Kaufman

Professor of Anatomy, Honorary Librarian of the Royal Medical Society Section of Anatomy, College of Biomedical and Clinical Laboratory Sciences, University of Edinburgh, Hugh Robson Building, George Square, Edinburgh, EH8 9XD

I thought that the members of the Society might be interested in learning about an "engraving" that hangs rather inauspiciously on one of the walls of the Society's Library in Bristo Place (figure 1). This item is of interest in several regards, but principally because no copy of it is available in the Reference Collection of the Royal Commission on Ancient and Historical Monuments of Scotland (RCAHMS) in Bernard Terrace, Ed-

inburgh. A detailed analysis of its features, however, reveals that this image is in fact a photograph of a very rare etching. The original is an anonymous etching that measures 23.9 by 41.3cm including the fine border line around it. It is based on a drawing by the architect George Smith (located in the Daniel Wilson scrapbooks, Vol 1, p 78, in the Library of the National Museums of Scotland). It is likely that